

Patellofemoral Osteoarthritis: Treatment with Autologous Bone Marrow Mononuclear Cells and Arthroscopic Surgery, a Prospective Study

Marcus Valladares Guimarães^{1*}, Paula Alexandra da Graça Morais Rios², Milton Artur Ruiz³, José Carlos Pinto Noronha⁴, Dalton Lopes Terra⁵ and Jose Fabio Santos Duarte Lana⁶

¹Orthopedist, D.A.B.R.M., F.A.A.R.M., Member of Brazilian Society of Orthopedic and Traumatology, Nucleus of Orthopedics and traumatology - (NOT) Belo Horizonte, Brazil.

²Biologist, Federal University of Juiz de Fora, MG, Brasil.

³Co-ordinator of Bone Marrow Transplant and Cellular Therapy Unit, Portuguese Charity Association of São José do Rio Preto - (PCASJRP) São José do Rio Preto, Brazil.

⁴Orthopedist, PhD, Research at the Aviero University, Portugal.

⁵Orthopedist, Member of Brazilian Society of Orthopedic and Traumatology, Nucleus of Orthopedics and traumatology - (NOT) Belo Horizonte, Brazil.

⁶Director of Bone and Cartilage Institute – (IOC) Indaiatuba, Brazil, Orthopedic Surgeon, Pain Interventionist, Sports Medicine D.A.B.R.M., F.A.A.R.M.

*Correspondence:

Marcus Valladares Guimarães, Nucleus of Orthopedics and Traumatology (NOT), Rua Aimorés 2125, Belo Horizonte, Minas Gerais, Brazil, 30140-072, Tel: +55 31 3349-2600, Fax: +55 31 3349-2638, E-mail: mvg@ortopediamarcusvguimaraes.com.

Received: 04 January 2018; Accepted: 14 February 2018

Citation: Guimaraes MV, Rios PAGM, Ruiz MA, et al. Patellofemoral Osteoarthritis: Treatment with Autologous Bone Marrow Mononuclear Cells and Arthroscopic Surgery, a Prospective Study. Stem Cells Regen Med. 2018; 2(1): 1-6.

ABSTRACT

Objective: The aim of this study was to evaluate the treatment using BMMCs and arthroscopy in PF OA through functional questionnaires and MRI evaluations in a two year follow up. The use of mononuclear cells derived from bone marrow (BMMCs) is under investigation, and in vitro and pre-clinic studies showed promisor results. In comparison to the mesenchymal stem cells (MSC), the effectiveness is lower, however the costs for manipulation and laboratory handling make it difficult to use in clinical practice.

Design: This was a pilot, longitudinal and prospective trial and 8 patients with patellofemoral osteoarthritis who met the study criteria were included. All of the patients underwent arthroscopic debridement and received an injection of autologous BMMCs. Clinical outcomes were evaluated using SF-36 and the TLKSS questionnaire at baseline, one and two years after the procedure.

Results: In this study, an improvement in all of the evaluated parameters of the questionnaire was verified even after two years following the applications. The functional score of TKLSS showed a significant improvement in one and two years in comparison to the baseline ($p < 0.001$). A significant improvement in SF-36 for all of the domains ($p < 0.001$) was also verified. In addition, an improvement in the MRI images of the patients was noticed, which indicates patellar cartilage recovery.

Conclusion: The procedure of the arthroscopy and the application of BMMCs has proved promising results to reduce the signs of PF OA and ensure the patient satisfaction with a safe return to social life and sports practice. The completed questionnaire confirmed a clear improvement and a strong impact on the quality of life of the patients with the regeneration of their articular cartilage and restored subchondral bone. These results offer a wide perspective for future studies with the use of BMMC to treat articular diseases.

Keywords

Patellofemoral joint, Osteoarthritis, Bone marrow mononuclear cells.

Introduction

Little attention has been given to the patellofemoral (PF) joint; however it is important to note that this compartment is involved in approximately 65% of individuals with knee osteoarthritis (OA) [1]. The disease impacts the daily activities such as walking and stair-climbing and leads to a loss of functional independence and quality of life. Large articular cartilage lesions of the knee PF compartment present specific difficulties during the clinical practice. When the conservative treatment fails to control the symptoms and a functional limitation occurs, surgery should be considered in order to treat the lesioned cartilage and the anatomical abnormalities. Typical procedures include the realignment surgery of the proximal patella, the reconstruction of the medial patellofemoral ligament and the reconstruction of the intercondylar area [2,3]. Even when properly treated, PF complications may eventually lead to the degeneration of the cartilage layer and the subsequent exposure of the subchondral bone, resulting in osteoarthritis.

Since cartilage has a limited regenerative capacity, all abnormalities are considered problematic. It has been usually accepted that the lesions of the articular cartilage, which do not penetrate the subchondral bone, are not repaired. Conversely, when penetration occurs, the lesions are repaired by the formation of fibrocartilage [4]. This tissue does not have the biochemical capacity of the hyaline cartilage found in the joint [5]. The traditional methods employed in the regeneration of articular cartilage anomalies include microfractures, multiple perforations, abrasion and mosaicplasty, with limited results [6,7]. Deciding the best applicable procedure is often difficult as there is no defined top alternative [2]. Three recent reviews tried to determine the best treatment for patellofemoral osteoarthritis (PFOA), but the results were inconclusive [2,3,8]. The arthroscopy procedure can include shaving chondroplasty, partial meniscectomy, and/or loose body removal. This is apparently a low-risk procedure and can provide a short duration of reduced symptoms. Currently, in the literature, this technique has been questioned in terms of effectiveness; however, many patients end up receiving knee arthroscopy, as they are not yet a good candidate for arthroplasty [9].

In this way, the search for a new treatment capable of helping and diminishing degeneration becomes valuable.

Cellular therapy has been studied for osteoarthritis treatment purposes and some investigations have focused on bone marrow mononuclear cells (BMMCs). The BMMC suspension consists of a heterogeneous population of cells, including mesenchymal stem cells (MSCs), hematopoietic stem cells (HSCs), hematopoietic progenitor cells (HPCs), endothelial progenitor cells (EPCs), adipocytes, macrophages, monocytes, neutrophils and platelets [10,11]. It is important to note that MSCs are a relatively rare population of cells within bone marrow (0.01%-0.001% of BMMCs). The therapy with BMMCs led to a weaker, albeit

significant therapeutic effect, when compared with the bone marrow mesenchymal stem cells (BMSCs). The efficacy of BMMCs is related to the HSC population, with the secretion of a variety of cytokines and growth factors and may act through paracrine signaling to enhance the survival and proliferation of BMSCs [10]. In 2014, Song et al., published one pre-clinical study with promising results, suggesting that even with a lower proportion of MSCs, BMMCs exert a reasonable regeneration effect on cartilage and the non-MS-C component may play an important role in this process. In this context, we believe that a combined treatment including arthroscopic debridement, lavage and local administration of the autologous fraction of the BMMCs can improve the articular function and the quality of life of the patients through a simple and secure procedure with a low morbidity rate.

The aim of this study was to evaluate the treatment using BMMCs and arthroscopy in PF OA through questionnaires and MRI evaluations in a two year follow up.

Material and Methods

Research Design

This was a pilot, longitudinal and prospective study. After a review and approval by the institutional ethics committee, the volunteers underwent cell collection and received treatment from the interventionist. Clinical and radiological evaluations were made before the procedure and then two years later. Questionnaires such as Short Form 36 (SF-36) and the Tegner-Lysholm Knee Scoring Scale (TLKSS) were used for quality of life and functional condition of the knee, respectively. These evaluations were made at baseline, one year and two years after the procedure. The grade of osteoarthritis was verified through the Outerbridge classification.

Patients

The study was conducted in the Nucleus of Orthopedics and Traumatology, in Belo Horizonte, MG, Brazil from June 2012 to January 2016. Eight patients were enrolled in our study. All eight patients were evaluated and deemed eligible for participation in this study. These patients were operated on between June 2012 and January 2014. The study was approved by the Orthopedics and Traumatology Center Ethics Committee of Belo Horizonte (authorization number: 01/2012) and all participants signed an informed consent form. Patients with a positive diagnostic for arthritis, obtained via magnetic resonance imaging (MRI) and corresponding radiological evidence of the affected knee were selected for the treatment. The inclusion criteria for the study were: 30- 80 years of age; non-reactive and negative results for rheumatic autoimmune disease and a diagnostic of PF OA obtained by the analysis of MRI. The exclusion criteria were: a 5-year malignancy diagnostic prior to the procedure; pregnancy or breast-feeding; active neurological disease; uncontrolled endocrine disorders (diabetes, hypothyroidism); active cardiac condition or respiratory disease (dependent on medication); positive or reactive tests for syphilis; Chagas disease; B, C, or HIV1+2 and HTLV1+2 hepatitis serological markers [12].

Patients were screened for clinical and demographic characteristics

and baseline assessment. Patients were followed for two years and they were submitted to one more follow-up evaluation two years after the procedure, where they completed SF-36 and TLKSS questionnaires and did clinical, functional, and radiological evaluation. The SF-36 and TLKSS evaluations were regularly performed in one and two years after the procedure. Radiology was performed two years after the application.

Cells preparation

The procedure was conducted at a clinical setting. Patients were not allowed to use NSAIDs and corticosteroids for three months after the treatment.

For sample removal, the patient was placed in a prone position on the Criovida® operating table. After the proper asepsis of the pelvis, the posterior superior iliac crest was anesthetized with 20 ml of lidocaine 1%. Four 20 ml syringes were each filled with 1ml of heparin (5000 UI). Puncture aspiration of the area anesthetized was performed with an Osgood-type myelogram needle. After being filled, the syringes were properly capped and homogenized. An average of 52 ml (30-87) of bone marrow material was collected from each patient. Due to the pain and anxiety, the fifth and the eighth patient did not consent to have a larger amount collected. The samples were kept in cold storage and prepared between 12-18 hours after the collection. BMSCs were sorted and isolated using a Ficoll® method (Ficoll-Paque PREMIUM 1.073 GE) and a Sepax® separator CS-900.2 - Biosafe – Switzerland. Ficoll was used to isolate lower-density human mononuclear cells (e.g., mesenchymal stromal cells or monocytes). After the separation of cells, the mononuclear cells were washed two times using a solution of saline and 20% of autologous albumin. This mixture was centrifuged at 400 x g for 10 minutes in order to remove the Ficoll. After the second wash, the cells were resuspended in the same solution of saline and autologous albumin and then transferred into a sterile syringe. The average surgical time was 12 minutes. One aliquot of the cells was used to quantify the cell content through a hematological counter (KX21 Roche).

Intervention procedure

The knee was washed with an Arthrex® pump filled with saline solution and the pressure used was 40 mmHg. 20 ml of BMSCs were handled via arthroscopic superolateral parapatellar articular puncture after the arthroscopic debridement of the PF using an Arthrex® shaver, for all the patients. Arthroscopy was performed in all patients. Anesthesia was performed by epidural block with Marcaine. The patients were placed in a dorsal decubitus position. The lower limb marked for operation was fixed in a legholder and a pneumatic cuff was maintained at the root of the limb. Vascular emptying was performed by compression with a search strip and the tourniquet pump was operated with a pressure of 300mmHg for an average time of 15 minutes. The arthroscopic access was performed by the medial and lateral para-patellar portals. An inventory of the knee was performed to rule out femorotibial arthrosis and meniscal injury. An area of patellofemoral control larynx was debrided with a shaver (mechanical debridement) in order to expose the subchondral bone. The joint was washed

with 0.9% saline solution. An intra-articular needle was placed via lateral access and direct vision with the arthroscope. The arthroscope was removed, the accesses sutured and a bandage was applied. BMSC injection was performed by the aforementioned needle.

Results

Patients

Eight patients were included in the study: four men and four women. The average age was 52.5 years (37-76 years of age). Seven patients had a compromised right knee; one patient had a compromised left knee. All the patients presented grade 4 in the Outerbridge classification (complete erosion of the cartilage with bone exposure). In regards to racial classification, two patients were identified as Caucasian while six other patients were identified as brown. Regarding comorbidities, one patient presented type 2 diabetes mellitus, controlled with medication. Due to complaints about the knee, none of the patients practiced physical activities. The characteristics of the patients are described in the table 1.

Patients	8
Gender (M:F)	4:4
Mean age	52.5 years
Ethnicity	75% Brown
	25% Caucasian
Outerbridge grade	4 (100%)
Comorbidities	12.5% type 2 Diabetes mellitus

Table 1: Patients casuistic.

All the patients had previously undergone a one-year conservative treatment with the administration of non-hormonal anti-inflammatory drugs and physiotherapy treatment. All patients discontinued the use of anti-inflammatories before the treatment. Regarding treatment alternatives while taking into consideration the clinical condition of patients, none of them agreed to have a total knee replacement (arthroplasty).

Cell content

As described in table 2, different volumes of bone marrow from the posterior iliac crest were collected, varying from 30 mL to 87 mL. The final volume injected was the same for all patients (20 mL). However, the concentration of BMSCs was different between 0.4 – 3.1 x10⁸ cells/μL, due to the variation of volume collected.

Patients	Volume of Bone Marrow Collected (mL)	Final volume administered (mL)	BMSC (cells/μL)
1	68	20	1.4 x 10 ⁸
2	58	20	1.3 x 10 ⁸
3	87	20	3.1 x 10 ⁸
4	81	20	2.4 x 10 ⁸
5	44	20	0.8 x 10 ⁸
6	73	20	1.04 x 10 ⁸
7	56	20	1.4 x 10 ⁸
8	30	20	0.4 x 10 ⁸

Table 2: Characteristics of the BMSC samples as description of the

volume collected and administered and the concentration.

Clinical evaluation – TLKSS and SF-36

The results obtained with the use of the TLKSS are shown in table 3. The average score before the treatment (basal) reached 48.3 points. One year after the treatment it reached 97.3 and then at the two-year mark it reached 96.7. The increase in score after the treatment represents an improvement in the functional condition of the knee. This increase was significant in comparison with basal and one year after treatment ($p < 0.001$) and no significant differences between one and two years after treatment were observed ($p > 0.1$). There was no loss of follow-up during this study among the patients included.

	Scoring by topic	Basal	1 year	2 years
Limp	Never = 5	0	8	8
	Light / periodic = 3	4	0	0
	Intense and continuous = 0	4	0	0
Support	None = 5	8	8	8
	Cane / Crutch = 2	0	0	0
	Impossible = 0	0	0	0
Locking	None = 15	0	8	8
	Feels like, not real = 10	0	0	0
	Occasional = 6	4	0	0
	Frequent = 2	4	0	0
	Joint locking during examination = 0	0	0	0
Instability	Never = 25	8	8	8
	Rarely, while practicing sports = 20	0	0	0
	Frequently, while practicing sports = 15	0	0	0
	Occasionally, during daily activities = 5	0	0	0
	In every step = 0	0	0	0
Pain	None = 25	0	7	6
	Inconsistent or during heavy exercise = 20	0	1	1
	Continuous during heavy exercise = 15	0	0	1
	Continuous during or after walking more than 2 km = 10	0	0	0
	Continuous during or after walking less than 2 km = 5	1	0	0
	Continuous = 0	7	0	0
Sweeling	None = 10	0	8	8
	With heavy exercise = 6	0	0	0
	With regular exercise = 2	6	0	0
	Impossible = 0	2	0	0
Stair climbing	No difficulty = 10	0	7	6
	Slight difficulty = 6	0	1	2
	One step at a time = 2	6	0	0
	Impossible = 0	2	0	0
Squatting	No difficulty = 5	0	4	5
	Slightly difficulty = 4	0	4	3
	Not beyond 90 degrees = 2	8	0	0

Table 3: Results of patients evaluation under the Lynsholm Scale in basal, one and two years after treatment.

Patient evaluation completed after one and two years of treatment showed significant amelioration of the pain domain with a clear improvement of other conditions, particularly the positive evolution of the emotional skills reflected in their social reintegration and sports practice. The average, minimum and maximum values of scores among the patients are shown in table 4. The increase in SF-36 score from basal to one year was significant ($p < 0.001$) for all domains (mental health $p = 0.02$). A statistical difference was found in mental health and general state of health ($p > 0.01$) in comparison between one and two years after the treatment with signs of improvement.

SF-36 Domains	Basal	1 year	2 years
Functional skills	10 (0-75)	90 (75-100)	90 (75-100)
Physical limitation	50 (0-75)	100 (97.5-100)	100 (97.5-100)
Pain	20 (10-72)	80 (72-100)	100 (97.5-100)
General state of health	30 (0-80)	67 (40-80)	82 (65-90)
Vitality	55 (25-100)	70 (40-100)	72 (40-100)
Social skills	33 (0-100)	100 (97.5-100)	100 (97.5-100)
Emotional skills	25 (0-100)	87.5 (66.7-100)	87.5 (66.7-100)
Mental health	60 (52-88)	68 (48-100)	76 (64-100)

Table 4: Mean, minimum and maximum of patients score obtained at basal time, one and two years after treatment using SF-36.

There were no adverse reactions, like local infections or complaints about the intra-articular administration of BMSC.

Regarding clinical conditions, during the physical evaluation before treatment, all patients reported severe patellar pain and gross crackling under patellar compression. One year later, two patients reported a much lighter crackling while this same observation was absent in the other six patients. Four patients informed recurrent pain at the lower end of the patella in the treated knee until two years, which ceased after stretching sessions, cold compress and muscle strengthening.

The review of MRI revealed osteophytes as well as reduction or lack of cartilage in the patellofemoral compartment. Six of the patients who had an increased patellar sign in T2 also displayed a significant improvement of the patellofemoral chondral cap without any increase of patellar sign (Figure 1).

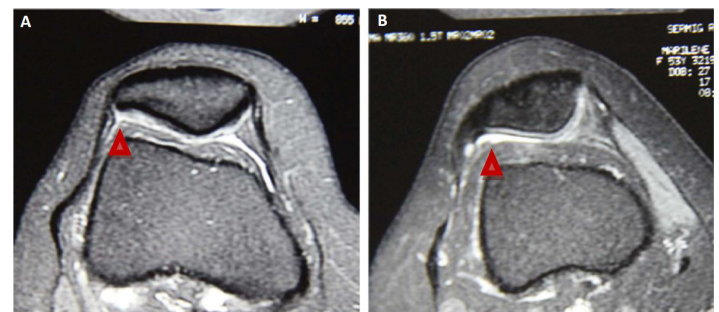


Figure 1: Female patient, 76 years old, axial MRI of the knee image

before treatment showing discontinuity of patellar cartilage (A). MRI image of the knee after a year of treatment showing recovery of the patellar cartilage (B).

Discussion

In this study, only 8 patients were included but, despite the small sample size, promising results were still obtained, which were applicable to post-treatment evaluation, even for patients that received less quantity of BMMCs.

Relative to the clinical evaluation, the TLKSS, a significant improvement in the functionality of the knee was verified in the first year which lasted until the two-year mark. Also, during the evaluation of the eight domains of the SF-36 before treatment, a low score was observed under the pain domain along with a great impact on the functional capacity and limitation of the patients' physical, social and emotional conditions. The patient evaluation completed after one and two years of treatment showed a significant improvement of the pain domain with a clear improvement of the conditions mentioned above, particularly the positive evolution of the emotional skills reflected in their social reintegration and sports practice. Four patients informed recurrent pain at the lower end of the patella in the treated knee until two years, which ceased after stretching sessions, cold compress and muscle strengthening. This improvement was also verified in the MRI of some patients.

In the literature, the BMMC potential to regenerate the articular cartilage is described in pre-clinical studies [13,14] and few clinical trials with a reduced number of patients or even case reports using the bone marrow components to treat orthopedic conditions [15,16].

Centeno et al., studied nucleated cells of the bone marrow in the regeneration of severely degenerated human hip [17]. For this investigation, a bone marrow sample was collected and centrifuged in order to concentrate nucleated cells. Two harvested bone marrow were administered in a one month interval. A significant change in 15 degrees of the hip extension was verified. According to a self-reported functional index, changes in function were observed. After 12 weeks, the questionnaire showed an improvement of one level in travel, recreation, and standing tolerance. An improvement of two levels in walking distance and sitting tolerance was also verified. MRI images described apparent partial articular surface neocortex regeneration in a severely degenerated hip. Positive results obtained via the use of fresh cells harvested from bone marrow were listed in this case report. Slynarski et al., evaluated the effectiveness of fresh bone marrow and periosteum transplantation in the treatment of traumatic or degenerative cartilage defects [16]. In this study, 14 patients were selected. The harvested bone marrow was injected under the sutured periosteum. A significant improvement in 57% of the patients was verified, who then returned to their regular activities in 3 months' time. An improvement in pain was also observed in 6 months, however, 17% of patients were not able to return to their previous physical activity routine. MRI images revealed surfaces with correct contours and continuity in 13 patients, showing once

again the beneficial results by utilizing bone marrow cells. On the other hand, the use of MSCs derived from bone marrow has been employed by researchers [18,19] with promising results.

It is important to note, however, that the cultivation of cells involves high costs and good manufacturing practice (GMP), which means that there is a complex regulation process. BMMCs permits direct processing of cells in the operating room, eliminating the need for cell culture while encouraging immediate autologous administration, thus allowing transplantation to be performed in "one step", leading to reduced costs, lower risk of biological contamination and no requirement for a GMP facility [20].

BMMCs have reasonable potential as an alternative therapeutic option for OA and relatively low costs, however, its long-term effects require further evaluation. In clinical studies, it was verified that transplantation of BMMCs retards the progress of OA, although not to the same extent as BMSCs.

The clinical data on BMMCs are emerging, however, due to costs, legislation and potential benefits, the use of BMMCs is favorable to treat OA, but larger randomized controlled trials with a larger number of patients are still required for effectiveness. This study revealed results of clinical follow-up of one and two years where the patients' complaints about pain were reduced. MRI images showed an improvement of the chondral cap. A biopsy would be necessary to determine the actual nature of the tissue repair. Another interesting finding was the reduction in the size of the edematous subchondral spots, evidenced in the MRI. These results can be attributed to the decrease of the pro-inflammatory proteins like as TNF- α and prostaglandin E2. Also, cell therapy has the capacity to increase gene expression of collagen type II and aggrecan and decrease the metalloproteinase 13. All these changes promote collective improvement in histological and macroscopic evaluation verified in animal studies [12].

The limitations of this study were attributed to the use of subjective evaluation, such as questionnaires and the concentration of the administered BMMCs which was different in all the patients.

Conclusion

The arthroscopy procedure and application of BMMCs have proven to be quite promising in reducing the signs of PF OA, ensuring patient satisfaction in regards to a safe recommencement of sports practice and social life. The completed questionnaire confirmed a clear improvement and a strong impact on the quality of life of patients with the regeneration of their articular cartilage and subchondral bone restoration. These results offer a wide perspective for future studies with the use of BMMC to treat articular diseases.

List of Abbreviations

BMMCs = Bone Marrow Mononuclear Cells, PF = Patellofemoral, OA = Osteoarthritis, MSC = Mesenchymal Stem Cells, SF-36 = Short Form 36, TLKSS = Tegner-Lysholm Knee Scoring Scale, MRI = Magnetic Resonance Imaging, HSC = Hematopoietic Stem

Cell, HPCs = Hematopoietic Progenitor Cells, EPCs = Endothelial Progenitor Cells, BMSCs = Bone Marrow Mesenchymal Stem Cells, NSAIDs = Non-steroidal anti-inflammatory drug.

References

1. Hunter DJ, Harvey W, Gross KD, et al. A Randomized Trial of Patellofemoral Bracing for Treatment of Patellofemoral Osteoarthritis. *Osteoarthritis Cartilage*. 2011; 19: 792-800.
2. Noyes FR, Barber-Westin SD. Advanced Patellofemoral cartilage lesions in patients younger than 50 years of age: is there an ideal operative option?. *Arthroscopy*. 2013; 29: 1423-1434.
3. Mouzopoulos G, Borbon C, Siebold R. Patellar chondral defects: review of challenging entity. *Knee Surg Sport Traumatol Arthrosc*. 2011; 19: 1990-2001.
4. Steadman JR, Briggs KK, Rodrigo JJ, et al. Outcomes of microfracture for traumatic chondral defects of the knee: average 11-year follow-up. *Arthroscopy*. 2003; 19: 477-484.
5. Horas U, Pelinkovic D, Herr G, et al. Autologous chondrocyte implantation and osteochondral cylinder transplantation in cartilage repair of the knee joint. A prospective, comparative trial. *J Bone Joint Surg Am*. 2003; 85: 185-192.
6. Matsusue Y, Yamamuro T, Hama H. Arthroscopic multiple osteochondral transplantation to the chondral defect in the knee associated with anterior cruciate ligament disruption. *Arthroscopy*. 1993; 9: 318-321.
7. Larsen KH, Andersen TE, Kassem M. Bone and cartilage repair using stem cells. *Ugeskr Laeger*. 2010; 172: 2616-2619.
8. Van Jonbergen HP, Poolman RW, van Kampen A. Isolated patellofemoral osteoarthritis. A systematic review of treatment options using the GRADE approach. *Acta Orthop*. 2010; 81: 199-205.
9. Steadman JR, Briggs KK, Matheny LM, et al. Ten-year survivorship after knee arthroscopy in patients with Kellgren-Lawrence grade 3 and grade 4 osteoarthritis of the knee. *Arthroscopy*. 2013; 29: 220-225.
10. Soltan M, Smiler D, Choi JH. Bone marrow: orchestrated cells, cytokines, and growth factors for bone regeneration. *Implant Dent*. 2009; 18: 132-141.
11. Lei SH, Guo L, Yue HY, et al. Marrow stromal stem cell autologous transplantation in denervated fracture healing: an experimental study in rats. *Orthop Surg*. 2013; 5: 280-288.
12. Song F, Tang J, Geng R, et al. Comparison of the efficacy of bone marrow mononuclear cells and bone mesenchymal stem cells in the treatment of osteoarthritis in a sheep model. *Int J Clin Exp Pathol*. 2014; 7: 1415-1426.
13. Kaplan JM, Youd ME, Lodie TA. Immunomodulatory Activity of Mesenchymal Stem Cells. *Curr Stem Cell Res Ther*. 2010; 29: 45-56.
14. Crovace A, Favia A, Lacitignola L, et al. Use of autologous bone marrow mononuclear cells and cultured bone marrow stromal cells in dogs with orthopaedic lesions. *Vet Res Commun*. 2008; 32: S39-44.
15. Centeno CJ, Busse D, Kisiday J, et al. Increased knee cartilage volume in degenerative joint disease using percutaneously implanted, autologous mesenchymal stem cells. *Pain Physician*. 2008; 11: 343-353.
16. Slynarski K, Deszczynski J, Karpinski J. Fresh Bone Marrow and Periosteum transplantation for Cartilage Defects of the Knee. *Transplantation Proceedings*. 2006; 38: 318-319.
17. Centeno CJ, John Kisiday, Freeman M, et al. Partial Regeneration of the Human Hip Via Autologous Bone Marrow Nucleated Cell transfer: A Case Study. *Pain Physician*. 2006; 9: 253-256.
18. Davatchi F, Abdollahi BS, Mohyeddin M, et al. Mesenchymal stem cell therapy for knee osteoarthritis. Preliminary report of four patients. *Int J Rheum Dis*. 2011; 14: 211-215.
19. Emadedin M, Aghdami N, Taghiyar L, et al. Intra-articular injection of autologous mesenchymal stem cells in six patients with knee osteoarthritis. *Archives Iranian Med*. 2012; 15: 422-428.
20. Giannini S, Buda R, Vannini F, et al. One-step bone marrow-derived cell transplantation in talar osteochondral lesions. *Clin Orthop Relat Res*. 2009; 467: 3307-3320.