

Research Article

Autologous Platelet Rich Plasma-A Biological Therapeutic Option for Retrocalcaneal Bursitis and its Associations

Madhan Jeyaraman^{1*}, Vishalkumar S Patel², Hardik J Dhamshania¹, Naveen Jeyaraman³, Preethi Selvaraj⁴

¹Department of Orthopaedics, JJM Medical College, Davangere, Karnataka, India

²Department of Orthopaedics, Navodhaya Medical College and Research Institute, Raichur, Karnataka, India

³Department of Orthopaedics, Kasturba Medical College, Manipal, Karnataka, India

⁴Department of Community Medicine, SRM Medical College and Research Centre, Chennai, India

***Corresponding Author:** Madhan Jeyaraman, Department of Orthopedics, JJM Medical College, Davangere, Karnataka, India, Tel: 8310600785; E-mail: madhanjeyaraman@gmail.com

Received: 13 April 2019; **Accepted:** 24 April 2019; **Published:** 29 April 2019

Abstract

Background: Retrocalcaneal bursitis is the inflammation of the bursa between the anterior aspect of the Achilles and posterior aspect of the calcaneum which is associated with achilles tendinitis, plantar fasciitis, calcaneal spurs, fibromyalgia and rheumatoid arthritis.

Objectives: This study is conducted to review a series of patients prospectively with symptomatic retrocalcaneal bursitis and its associations to determine if PRP injections (1) provide symptomatic relief, (2) improved VAS and AOFAS scores and (3) alleviation of need of surgery.

Materials and Methods: After screening of cases, 128 cases entered into the study and have been treated with an autologous platelet rich plasma injection with due pre and post procedural care. The cases are followed up on day 0, at the end of 1st week, 1st and 6th month for pain and range of movements. The patients are followed up for complications and the data were analyzed statistically.

Results: Out of 128 cases, 76 patients (59.37%) improved with 1st dose and a further 38 patients (29.68%) with a 2nd dose of autologous PRP injection with an interval of 3 weeks from the first dose. A total of 89.05% of patients, who got treated with autologous PRP injection, had a good clinical and functional outcome even at the end of 1 year of injections and presented with statistically significant results with a p value <0.001. No adverse reactions and serious complications are noted in the study participants.

Conclusion: The autologous PRP injection is considered superior in treatment of retrocalcaneal bursitis, which minimise the pain and improve the functional quality of life.

Keywords: Platelet rich plasma; Plantar fasciitis; Retrocalcaneal bursitis; Achilles tendinitis

1. Introduction

Retrocalcaneal bursitis is the inflammation of the bursa between the anterior aspect of the Achilles and posterior aspect of the calcaneum which is most commonly seen in professional athletes. Retrocalcaneal bursitis is also associated with achilles tendinitis, plantar fasciitis, calcaneal spurs, fibromyalgia and rheumatoid arthritis [1]. The embryological origin of the plantar fascia seems to be united with the Achilles tendon [2] and this connection comprises a layer of periosteal fibers that declines in thickness and elastic properties with aging [3]. The ubiquitous presence of hyaluronate within plantar fascia enables the gliding of fibrous bundles and acts as an efficient shock absorber and also serving an anti-inflammatory purpose [4]. The chondrocytes found near the heel insertion expresses a cartilaginous metaplasia that gradually reduces the connection between the Achilles tendon and the plantar fascia, reducing PF elasticity as a consequence [5]. The strong correlation between the thickness of plantar fascia and Achilles paratenon suggest in the case of plantar fascia thickening the characteristics of Achilles tendon and paratenon should also be evaluated. The patients with retrocalcaneal bursitis and its associations are unaware of the need for prompt treatment to prevent further complications. The various modalities of management of retrocalcaneal bursitis are pharmacological management, physical therapy, biological therapy and surgical management.

1.1 Objectives

To prospectively review a series of patients who have been treated with biological treatment with autologous platelet rich plasma injections for symptomatic retrocalcaneal bursitis and its associations to determine if PRP injections (1) provide symptomatic relief, (2) improved the visual analogue scale (VAS) score and functional AOFAS scores and (3) alleviation of need of surgery.

2. Materials and Methods

- Health care setup-Tertiary care hospital
- Setting-JJM Medical College, Davangere, Karnataka.
- Duration of the study-November 2016 to June 2018
- Type of the study-Prospective study
- Level of evidence-Level IV
- Sample size-211
- Selection of cases-Among 211 retrocalcaneal bursitis cases, 37 cases failed to satisfy the inclusion criteria, 25 cases lost follow up and 21 cases declined to participate the study as in Figure 1. The remaining 128

cases were taken up for this study who were treated with autologous platelet rich plasma injection as per our study protocol.

- The clinical entities involved in this study were retrocalcaneal bursitis with achilles tendinitis (n=37), retrocalcaneal bursitis (n=51) and retrocalcaneal bursitis with plantar fasciitis (n=40).

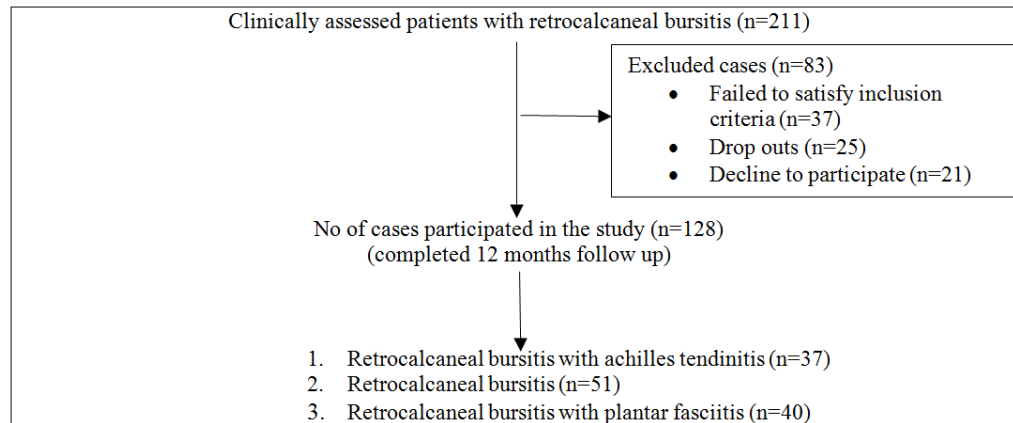


Figure 1: Patient's selection.

2.1 Inclusion criteria

- Patients with retrocalcaneal bursitis with achilles tendinitis, retrocalcaneal bursitis and retrocalcaneal bursitis with plantar fasciitis who have taken conservative treatment without any improvement from past 6 months
- Patients with recalcitrant chronic retrocalcaneal bursitis without any improvement from past 6 months
- Patients who gave consent for treatment with autologous PRP injection as per our protocol
- Regular visits in the out-patient department.

2.2 Exclusion criteria

- Patients with haemoglobin <10 gm/dL and platelet count <10⁵/μL
- Patients with corticosteroid injection at treatment site within 1 month
- Patients with tendo-achilles rupture
- Patients with local infection at the site of the procedure, HIV, Hepatitis B or C, septicaemia and other systemic disorders
- Patients refusal for PRP treatment as per our protocol.

After getting institute ethical committee clearance and informed written consent from the patients enrolled in our study, they were subjected for thorough clinical examination and to investigate the duration of the disease and the nature of management taken prior to autologous platelet rich plasma treatment. The baseline investigations and radiographic analysis such as plain x ray and ultrasound examination of the pathological sites were analyzed. All the cases were investigated for the usage of NSAIDs 72 hours prior and local steroid infiltration 4 weeks prior to autologous PRP injection. 20 cc of venous blood was withdrawn in 3.8% sodium citrate vacutainers and subjected

for 1st centrifugation at a rate of 3000 rpm for 10 minutes. Then the plasma was separated in plain vacutainers and subjected for 2nd centrifugation at a rate of 5000 rpm for 10 minutes. The resultant solution contain upper 2/3rd platelet poor plasma and lower 1/3rd platelet rich plasma. The procedure of platelet rich plasma preparation have been mentioned in Figure 2. Every 20 cc of venous blood yield 3-4 ml of platelet rich plasma solution. Before injecting PRP solution, add 10% of calcium chloride to PRP solution in the ratio of 1:10.

All the cases enrolled in the study were injected with 3-4 ml of autologous platelet rich plasma injection along the inflamed retrocalcaneal bursa, plantar fascia and achilles tendon. The techniques of injection of platelet rich plasma to retrocalcaneal bursitis and plantar fasciitis have been mentioned in figure 3 and 4. The sterile dressing and crepe bandage were applied at the injection site. The patients were trained for home based ankle exercises. All the patients were advised for protected weight bearing for minimum of 2 weeks and the pain was combated with ice pack application. The patients who came with recurrence of pain and symptoms were given with second dose of autologous PRP injection with a time interval of 3 weeks of first injection. The functional status and severity of pain around the ankle joint were charted according to VAS and AOFAS score both pre-procedurally on day 0 and post-procedurally at the end of 1st week, 1st and 6th month. All the cases were followed up for 1 year post injection to know the status of efficacy of autologous PRP injection.




Figure 2: Platelet rich plasma preparation; (a) Process of differential centrifugation; (b) Image showing 1st centrifugation with separation of blood components; (c) Image showing 2nd centrifugation with upper 2/3rd of PPP and lower 1/3rd of PRP solution.

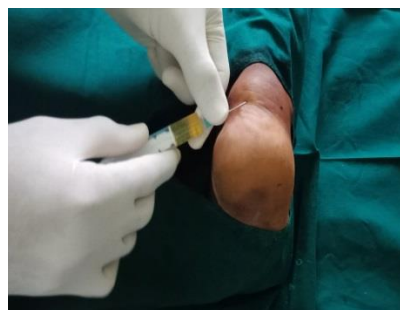

Figure 3: Technique of PRP injection to left retrocalcaneal bursitis.

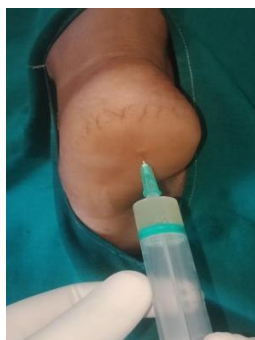

Figure 4: Technique of PRP injection to right plantar fasciitis.

3. Results

The data obtained from the participants of the study were subjected to repeated measures ANOVA test and the following results are obtained. The demographic details (Table 1), the number of PRP injections given to alleviate the disease (Table 2), the statistical analysis (Table 3) and the complications (Table 4) have been discussed.

Disease	Total	Male	Female	Minimum age in years	Maximum age in years	Mean age in years
Retrocalcaneal bursitis with achilles tendinitis	37	22 (59.45%)	15 (40.54%)	32	69	51.15
Retrocalcaneal bursitis	51	28 (54.90%)	23 (45.09%)	21	59	41.24
Retrocalcaneal bursitis with plantar fasciitis	40	21 (52.50%)	19 (47.50%)	29	70	52.51

Table 1: Patients distribution after elimination.

Out of 128 cases, 71 cases (55.46%) were males and 57 cases (44.53%) were females. The mean age of patients participated in our study were 48.30 years with minimum age of 21 years and maximum age of 70 years.

Disease	Total	No of patients cured with 1 st dose of autologous PRP (at end of 1 st month follow up)	No of patients cured with 2 nd dose of autologous PRP	No of patients with recalcitrant disease (at the end of 6 th month follow up)	No of recalcitrant disease patients cured at the end of 12 th month
Retrocalcaneal bursitis with achilles tendinitis	37	23 (62.16%)	11 (29.72%)	3 (8.10%)	2 (66.66%)
Retrocalcaneal bursitis	51	32 (62.74%)	14 (27.45%)	5 (9.80%)	2 (40.00%)
Retrocalcaneal bursitis with plantar fasciitis	40	21 (52.50%)	13 (32.50%)	6 (15.00%)	3 (50.00%)

Table 2: Number of PRP injections.

Disorder	Scoring	Repeated measures ANOVA test (p value)			
		Pre procedure	Post procedure		
			1 st week	1 st month	6 th month
Retrocalcaneal bursitis with achilles tendinitis (n=37)	VAS	0.691	0.274	0.001	<0.001
	AOFAS	0.671	0.091	0.056	<0.001
Retrocalcaneal bursitis (n=51)	VAS	0.459	0.047	0.003	<0.001
	AOFAS	0.875	0.056	0.061	<0.001
Retrocalcaneal bursitis with plantar fasciitis (n=40)	VAS	0.513	0.261	0.024	<0.001
	AOFAS	0.677	0.287	0.047	<0.001

Table 3: p value of repeated measure ANOVA test.

Out of 128 cases, 76 patients (59.37%) reported pain relief with one dose of autologous PRP injection at the end of 1st month follow up and 38 patients (29.68%) reported pain relief after 2nd dose of injection which was given at the interval of 3 weeks from the first dose. 14 patients (10.93%) presented with recalcitrant disease after 6 months of first dose. All 14 recalcitrant cases have been given with one more dose of autologous PRP injection. Out of 14 cases, 7 patients got cured by the end of the 12th month follow up. At the end of the 12th month, 1 case (33.33%) of retrocalcaneal bursitis with achilles tendinitis, 3 cases (60.00%) of retrocalcaneal bursitis and 3 cases (50.00%) of retrocalcaneal bursitis with plantar fasciitis remained as recalcitrant disease. Overall, our study showed a statistically significant difference between pre-procedural and post-procedural scores in subjective (VAS) and functional (AOFAS) scoring system. The patients, who took autologous PRP injection, showed a statistically significant (p < 0.001) improvement in all three clinical entities included in the study.

Disease	Total	Pain	Swelling	Recurrence
Retrocalcaneal bursitis with achilles tendinitis	37	17 (45.94%)	14 (37.83%)	1 (2.70%)
Retrocalcaneal bursitis	51	29 (56.86%)	19 (37.25%)	3 (5.88%)
Retrocalcaneal bursitis with plantar fasciitis	40	17 (42.50%)	13 (32.50%)	3 (7.50%)
Total no of cases	128	63 (49.21%)	46 (35.93%)	7 (5.46%)

Table 4: Complications.

The complications found in our patients were pain at the injection site in 63 cases (49.21%), swelling in 46 cases (35.93%) and recurrence of symptoms in 7 cases (5.46%). No other adverse reactions were noted in the patients participated in the study. All 7 recalcitrant cases were counselled for surgical management.

4. Discussion

There is a strong positive correlation and temporal association existing between the occurrence of plantar fasciitis, retrocalcaneal bursitis and achilles tendinopathy [1, 6].

4.1 Retrocalcaneal bursitis and Haglund deformity

Retrocalcaneal bursitis is the inflammation of the bursa between the anterior aspect of the Achilles and posterior aspect of the calcaneum. In some cases, retrocalcaneal bursitis may be caused by bursal impingement between the Achilles tendon and an excessively prominent posterosuperior aspect of the calcaneus (Haglund deformity). In Haglund disease, impingement occurs during ankle dorsiflexion. Retrocalcaneal bursitis is also associated with achilles tendinitis, plantar fasciitis, calcaneal spurs, fibromyalgia and rheumatoid arthritis. In retrocalcaneal bursitis, the pain is localized to anterior and 2 to 3 cm proximal to the achilles tendon insertion, pain with dorsiflexion and a bony prominence at achilles insertion [6].

4.2 Achilles tendinopathy

Achilles tendinopathy occurs in middle-aged and elderly patients with a tight heel cord. The mechanism of achilles tendinopathy is due to repetitive trauma leads to inflammation followed by cartilaginous and bony metaplasia, imbalance of dorsiflexors and plantar flexors, poor tendon blood supply, fluoroquinolone antibiotics and inflammatory arthropathy. The pathogenesis behind achilles tendinopathy is due to the abnormal vascularity 2 to 6 cm proximal to Achilles insertion in response to repetitive microscopic tearing of the tendon. The plain radiograph shows bone spur and intratendinous calcification. MRI shows disorganized tissue will show up as intrasubstance intermediate signal intensity and thickened tendons [6].

4.3 Plantar fasciitis

Plantar fasciitis is a chronic self-limiting condition due to overuse of plantar fascia, which is characterized by micro tears, the breakdown of collagen, and scarring. Between 4% and 7% of people have heel pain at any given time and about 80% of these cases are due to plantar fasciitis. The pain is usually most severe with the first steps of the day or following a period of rest. Pain is also frequently brought on by bending the foot and toes up towards the shin and may be worsened by a tight achilles tendon. In about a one-third of the population, both legs are affected. Most common site of abnormality in patients with plantar fasciitis is near the origin or enthesitis of the central band of plantar aponeurosis at medial plantar tubercle of calcaneus. Patient walk with an equinus gait to avoid placing pressure on painful heel. On examination, tenderness on the medial plantar calcaneal region as a sharp stabbing pain is felt. Passive ankle or first toe dorsiflexion elicits pain. When plantar fasciitis is bilateral, it is associated with rheumatoid arthritis, SLE and gout [7].

Platelet rich plasma, a potent “Orthobiologic”, is defined as the volume of supernatant containing plasma with platelet concentration of 10^5 - 10^6 above the baseline, which is a potent osteogenic, osteointegrative and osteorejuvenative agent [8]. The rationale behind platelet rich plasma in the management of retrocalcaneal bursitis

and its associations are due to the interplay between histopromotive factors and rejuvenating micromolecules present in the platelets. The binding of growth factor to target cell receptor induces a signal transduction mechanism which produces chemotaxis, cell proliferation and osteoblastic differentiation [9]. The growth factors undergo tyrosine autophosphorylation to catabolise the further phosphorylation of other growth factors [10-12]. The half life of growth factors are from minutes to hours. The growth factors can exert an inhibitory effect once a certain amount of concentration is reached. Once activated, the platelet rich plasma forms a coagulum which contain growth factors. About 70% of growth factors are released from α granules of platelets within 10 minutes of the injection. These growth factors rejuvenate the diseased and degenerated tissues. The dose response relationship of platelet rich plasma follows a sigmoid shaped curve.

Ferrero G, et al. injected autologous PRP under ultrasound guidance for 30 achilles tendinopathy and 28 patellar tendinopathy cases. All the patients were evaluated with VISA scale. At the end of 6th month follow up, VISA score drastically improved from the baseline. Ultrasound evaluation showed an improvement in fibrillar texture of diseased and degenerated tendons. They concluded that autologous PRP as a therapeutic option for achilles and patellar tendinopathy with a great accuracy [13]. Venkatesh Gupta, Divya Bandari conducted a study on autologous platelet rich plasma injection in 60 cases of tennis elbow and 40 cases of plantar fasciitis. The results of autologous PRP injection have been evaluated with VAS, DASH and FHSQ scoring system. Both groups of patients were clinically and functionally evaluated after 4th and 8th week of initial PRP injection, which showed statistically significant improvement in pain and quality of life [14].

In this article, we considered autologous platelet rich plasma injection as the biological and minimally invasive therapeutic option for retrocalcaneal bursitis and its associations. Which show the functional improvement in 76 patients (59.37%) with 1st dose of autologous PRP injection and a further 38 patients (29.68%) with 2nd dose of autologous PRP injection with an interval of 3 weeks from the first dose. A total of 89.05% of patients, who got treated with autologous PRP injection, had a good clinical and functional outcome even at the end of 1 year of injections and presented with statistically significant results with a p value <0.001.

5. Limitation

- No comparison group was considered in the study
- Standardization of PRP injection protocol has to be figured out.

6. Conclusion

Though the literatures available for autologous PRP therapy for retrocalcaneal bursitis are very less, we tried evaluating the efficacy and durability of autologous PRP therapy for retrocalcaneal bursitis and its associations which proved to improve the quality of pain and functional quality of life. Hence, we conclude the biological therapeutics of platelet rich plasma for retrocalcaneal bursitis is more beneficial than other pharmacological

modalities of treatment. Further RCT and meta analysis on PRP therapy for retrocalcaneal bursitis should come up which would guide the clinicians for better understanding of the disease and the treatment option.

Conflicts of Interest

Nil

Funding sources

Nil

Acknowledgements

None

References

1. Pekala PA, Henry BM, Pekala JR, et al. The Achilles tendon and the retrocalcaneal bursa. *Bone Joint Res* 6 (2015): 446-451.
2. Shaw HM, Vazquez OT, McGonagle D, et al. Development of the human Achilles tendon enthesis organ. *J Anat* 213 (2008): 718-724.
3. Snow SW, Bohne WH, DiCarlo E, et al. Anatomy of the Achilles tendon and plantar fascia in relation to the calcaneus in various age groups. *Foot Ankle Int* 16 (1995): 418-421.
4. Neuman MG, Nanau RM, Oruna L, et al. In vitro anti-inflammatory effects of hyaluronic acid in ethanol-induced damage in skin cells. *J Pharm Pharm Sci* 14 (2011): 425-437.
5. Kim PJ, Martin E, Ballehr L, et al. Variability of insertion of the Achilles tendon on the calcaneus: an MRI study of younger subjects. *J Foot Ankle Surg* 50 (2011): 41-43.
6. Jones DE. Retrocalcaneal Bursitis and Insertional Achilles Tendinitis. *Sports Med Arthroscopy Rev* 2 (1994): 301-309.
7. Martin J O'Malley, Turner Vosseller J, Yang Gu. Successful Use of Platelet-Rich Plasma for Chronic Plantar Fasciitis. *HSSJ* 9 (2013): 129-133.
8. Ramesh R, Madhan Jeyaraman, Prajwal GS. Autologous Platelet Rich Plasma Therapy in Orthopaedics-A Clinical Update. *Nat J Clin Orthop* 2 (2018): 33-36.
9. Simpson AHR. Mills L. Noble B: The role of growth factors and related agents in accelerating fracture healing. *J Bone Joint Surg Br* 88 (2006): 701-705.
10. Eduardo Anitua, Ramon Cugat, Mikel Sanchez. Platelet rich plasma in orthopaedics and sports medicine, Switzerland, Springer, (1st Edn.), Chapter 3 (2018): 47-64.
11. Anitua E, Andia I, Ardanza B, et al. Autologous platelets as a source of proteins for healing and tissue regeneration. *Thromb Haemost* 91 (2004): 4-15.
12. Sheth U, Simunovic N, Klein G, et al. Efficacy of autologous platelet rich plasma use for orthopaedic indications: a meta-analysis. *J Bone Joint Surg Am* 94 (2012): 298-307.

13. Ferrero G, Fabbro E, Orlandi E, et al. Ultrasound-guided injection of platelet-rich plasma in chronic Achilles and patellar tendinopathy. *Journal of Ultrasound* 15 (2012): 260-266.
14. Venkatesh Gupta, Divya Bandari. Autologous platelet rich plasma injection in tennis elbow and plantar fasciitis. *Current Orthopedic Practice* 27 (2016): 405-408.

Citation: Madhan Jeyaraman, Vishalkumar S Patel, Hardik J Dhamshania, Naveen Jeyaraman, Preethi Selvaraj. Autologous Platelet Rich Plasma-A Biological Therapeutic Option for Retrocalcaneal Bursitis and its Associations. *Journal of Orthopaedics and Sports Medicine* 1 (2019): 018-027.



This article is an open access article distributed under the terms and conditions of the [Creative Commons Attribution \(CC-BY\) license 4.0](https://creativecommons.org/licenses/by/4.0/)