

Received:  
4 May 2015Revised:  
7 June 2016Accepted:  
13 June 2016<http://dx.doi.org/10.1259/bjr.20150355>

Cite this article as:

Barile A, La Marra A, Arrigoni F, Mariani S, Zugaro L, Splendiani A, et al. Anaesthetics, steroids and platelet-rich plasma (PRP) in ultrasound-guided musculoskeletal procedures. *Br J Radiol* 2016; **89**: 20150355.

## REVIEW ARTICLE

# Anaesthetics, steroids and platelet-rich plasma (PRP) in ultrasound-guided musculoskeletal procedures

<sup>1</sup>ANTONIO BARILE, MD, <sup>1</sup>ALICE LA MARRA, MD, <sup>1</sup>FRANCESCO ARRIGONI, MD, <sup>1</sup>SILVIA MARIANI, MD, <sup>1</sup>LUIGI ZUGARO, MD, <sup>1</sup>ALESSANDRA SPLENDIANI, MD, <sup>1</sup>ERNESTO DI CESARE, MD, <sup>2</sup>ALFONSO REGINELLI, MD, <sup>3</sup>MARCELLO ZAPPIA, MD, <sup>3</sup>LUCA BRUNESE, MD, <sup>4</sup>EJONA DUKA, MD, <sup>4</sup>GIAMPAOLO CARRAFIELLO, MD and <sup>1</sup>CARLO MASCIOCCHI, MD

<sup>1</sup>Department of Biotechnological and Applied Clinical Sciences, University of L'Aquila, L'Aquila, Italy

<sup>2</sup>Department of Internal and Experimental Medicine, Magrassi-Lanzara, Institute of Radiology, Second University of Naples, Naples, Italy

<sup>3</sup>Department of Medicine and Health Sciences, University of Molise, Campobasso, Italy

<sup>4</sup>Department of Health Sciences, University of Milan, Milan, Italy

Address correspondence to: Prof. Antonio Barile

E-mail: [abarile63@gmail.com](mailto:abarile63@gmail.com)

## ABSTRACT

This review aims to evaluate the role of anaesthetics, steroids and platelet-rich plasma (PRP) employed with ultrasound-guided injection in the management of musculoskeletal pathology of the extremities. Ultrasound-guided injection represents an interesting and minimally invasive solution for the treatment of tendon and joint inflammatory or degenerative diseases. The availability of a variety of new drugs such as hyaluronic acid and PRP provides expansion of the indications and therapeutic possibilities. The clinical results obtained in terms of pain reduction and functional recovery suggest that the use of infiltrative procedures can be a good therapeutic alternative in degenerative and inflammatory joint diseases.

## INTRODUCTION

In the field of musculoskeletal diseases, infiltrative ultrasound-guided therapy is an effective treatment option.<sup>1-4</sup> This technique, nowadays, is increasingly being used in the treatment of diseases of the musculoskeletal system, owing to its minimally invasive approach, low anaesthesiological risk and the continuous advancements in materials and imaging equipment. The imaging guide is not necessary for infiltrative procedures, and many specialists are currently doing without; nevertheless, for radiologists, it represents an added value and is essential to provide the patient with safe and accurate treatments. Especially in the treatment of superficial lesions involving the soft tissues, ultrasound is an excellent leading technique, providing the operator with multiplanar and dynamic images of the examined structures; it also allows reaching the target structure with precision, avoiding damage to important anatomical structures (vessels, nerves *etc.*). This technique is operator dependent and requires a thorough knowledge of the anatomy and a good experience in diagnostic ultrasound imaging.<sup>2-4</sup>

## INFILTRATIVE TECHNIQUES

The ultrasound-guided approach can be performed with different techniques.

**Free-hand technique with axial or parallel access**  
This technique requires good manual skill from the operator, who must be able to coordinate the transducer and needles in real time and with both hands. It is especially indicated for the treatment of superficial sites. To visualize the needle, two conditions are required:

- To be visible to the operator, the needle must be introduced within the field of view of the transducer.
- To be visualized, the inclination of the needle, with respect to the transducer, must range from 60° to 90°. Between 0° and 60°, the needle will not be visible.<sup>3,4</sup>

### *Parallel access*

In parallel access, the needle is introduced parallel to the transducer. This approach is used specifically in the treatment of tendon and bursal disease of the shoulder, in epicondylitis and in the patellar and Achilles tendons.

### *Axial access*

Axial access can be performed only by free hand, in any anatomical site, both deep and superficial. The target area should be positioned at the centre of the image and the needle should be introduced in a point exactly in the middle of the largest side of the transducer, more or less vertically to the depth of the target. In this technique, the operator cannot see the needle when it is first introduced,

but only in the final stage when the needle reaches the target. This access is useful in anatomical sites where the proximity to important structures, such as vessels and nerves, does not allow the parallel orientation of the needle with respect to the transducer. In some cases, it could be helpful to perform these techniques with a combined approach.

#### Ultrasound-guided approach with pointing kit

This approach uses a pointing kit, applied on the transducer, which allows locating the needle perfectly by following the path on the ultrasound monitor. The guides can be angle fixed or multiangle (and are selected depending on the depth of the target). The advantage of using such a device is correlated to the ability to have a good view of the needle even when its inclination with regard to the ultrasound beam is not optimal. The application of the guide may be useful when infiltrating deep structures such as the hip. However, it has some drawbacks related to longer times of preparation and the need to use longer needles that can be manoeuvred from the outside.<sup>3,4</sup>

### PATIENT SELECTION CRITERIA

The patient will be recruited for the interventional procedure only after a careful selection and a correct assessment of his/her conditions. For each disease, it is necessary to carry out a series of preliminary tests, such as clinical and laboratory tests and diagnostic examinations. Only subsequently, the most appropriate treatment can be carried out.

Infiltrative articular and para-articular therapies, however, are an invasive act, and as such require informed consent from the patient and the respect of the rules of asepsis from the interventional radiologist and his team.<sup>3,4</sup> Informed consent is useful to establish a relationship of respect and trust between the doctor and the patient, a guided path of information through communication.

Sterility rules must be part of the knowledge of the interventional radiologist, because the greatest risk is that of septic joint inflammation. A sterile field setup is needed, with sterile gauze and the correct solution for disinfecting the skin (active ingredient: povidone iodine), sterile probe cover, sterile gel and disposable syringes of different sizes depending on the needs of the operator.

The diseases that are most frequently treated with musculoskeletal interventional radiology of the extremities are osteoarthritis, chondropathies, joint pain from chronic friction and overload, bursitis, synovitis and insertional tendinopathy.

### LOCAL ANAESTHETICS

#### Pharmacological aspects

Local anaesthetics are drugs that express their analgesic effect by reversibly interrupting nerve conduction in the administration site. Their mechanism of action is supposed to be nerve conduction blockade, interrupting the propagation of the action potential along axons through the sodium channel blockade (sodium channels are normally present in the lipid bilayer of the plasma membrane). When the neuron is stimulated, the sodium channel state changes from inactive to active, allowing the

passage of sodium ions and the beginning of depolarization. Local anaesthetics have a great affinity for certain receptors of sodium channels during the transition between active and inactive status. Local anaesthetics are a very heterogeneous class of compounds and can be divided into two categories: amino esters (procaine, chlorprocaine and tetracaine) and amino amides (prilocaine, etidocaine, lidocaine, mepivacaine, bupivacaine, ropivacaine and levobupivacaine), based on the type of bond of their intermediate chain.

The drugs, the most commonly used are listed below.

#### *Lidocaine*

Lidocaine is used more for its rapid absorption and onset; the effect lasts about 3 h. Its acid dissociation constant (pKa) of 7.7 allows rapid distribution to the extremities.

#### *Mepivacaine*

Mepivacaine has a pKa of 7.6 and a lower activity than lidocaine but slower absorption. The half-life is about 2–4 h. It also presents vasospasm effect, in contrast to other local anaesthetics. The administration form is a white powder soluble in water. In addition, a factor that should not be underestimated is that mepivacaine has no vasodilator effect, so it does not need the combined administration of a vasoconstrictor agent.

#### *Bupivacaine*

Bupivacaine has a pKa of 8.1. Its effects are similar to those of mepivacaine, but it possesses a long duration, up to 18–24 h, with slow absorption. At low doses, it predominantly has sensory blockade rather than motor blockade. It also has greater toxicity.<sup>5</sup>

#### *Ropivacaine*

Ropivacaine is a local anaesthetic of the amide type with a chemical structure similar to bupivacaine and mepivacaine. The physical and chemical properties are similar to those of bupivacaine. *In vitro* ropivacaine has fewer adverse neurotoxic and cardiotoxic effects. Compared with bupivacaine, ropivacaine has (at the same serum concentration) less motor blockade at low concentrations, less cardiac toxicity and lower lipid solubility. An interesting property of ropivacaine is the low vasodilatory effect.

#### *Procaine*

Procaine is a water-soluble drug that has a rapid absorption from the injection site and is hydrolyzed in para-aminobenzoic acid by a plasmic esterase.<sup>6</sup>

#### When and how

If the procedure is locally painful, local anaesthetics can be used, infiltrating the skin at the site of surgery.<sup>3,4</sup> The use of anaesthetics with an average duration of action allows for adequate coverage of pain and to some degree contributes to the patient comfort level in the following hours.<sup>7,8</sup>

#### Complications

The toxicity mediated by these drugs depends on the direct systemic effect, which from its site of administration moves in a circle, reaching the central and peripheral nervous system and

the cardiovascular system. Surely, the most serious side effect is represented by seizures. In addition to the nerve blockade, the role of local anaesthetics includes varying degrees of vasodilation and this contributes to the hypotension observed after administration of large doses of the drug. If the plasma concentration of the local anaesthetic continues to rise, it could lead to coma, respiratory arrest and possibly cardiovascular collapse. While it has been observed that most of the local anaesthetics have similar toxic effects on the central nervous system, it is interesting to note that bupivacaine has more adverse effects on the cardiovascular system. This concept turns out to be of enormous importance in all those procedures where bupivacaine is administered at high doses and in patients with predisposition to heart disease.

Apart from major side effects, there are minor effects including tremors, disorientation, dizziness, mydriasis, increased metabolism and body temperature, sweating, nausea and vomiting, bronchospasm, laryngeal oedema and respiratory collapse. The local manifestations may include rashes of various types, urticarial rash and pruritus. The first sign of systemic toxicity is drowsiness or a sense of sensory dulling, followed by lingual paraesthesia, tinnitus, visual disturbances and agitation. In severe poisonings, convulsions, coma and cardiorespiratory depression may occur. We can also witness rhythm disturbances, e.g. ventricular extra systoles, ventricular and supraventricular tachycardia and conduction defects.

Allergies to local anaesthetics are rare. Patients often report allergy to local anaesthetics, syncope or palpitations, events attributable to more adrenaline added to the solution or endogenously released in response to stress. Other reactions may be due to hypersensitivity to preservatives (methylparaben) and antioxidants dissolved in the solution, which serve to prevent microbial growth, while antioxidants prevent the oxidation of adrenaline. The allergic reactions are due to the activation of sensitized lymphocytes against an antigen that mediates a number of chain reactions.

The local toxicity of anaesthetics is not to be underestimated: ischaemic necrosis of tissues can, in fact, follow the injection of the anaesthetic. It may be due to the irritation given by the solution or by the vasoconstrictor effect of adrenaline.

Absolute contraindications to the use of anaesthetics are allergy medications, infections at the site of administration, vascular malformations at the site of application and pregnancy. Relative contraindications are severe patient conditions, haemophilia, leukemia, severe diabetes mellitus *etc.*, which should be evaluated from time to time in each individual patient.<sup>5-8</sup>

## STEROIDS

### Pharmacological aspects

Steroids are anti-inflammatory drugs of endogenous synthesis with different effects. They have an effect on the glucose metabolism, fluid and electrolyte balance and pituitary gland, with a negative feedback mechanism, and have an anti-inflammatory and immunosuppressive effect.<sup>9</sup>

They can be classified into mineralocorticoids (e.g. aldosterone), which control the sodium and water balance, and glucocorticoids

(e.g. cortisol),<sup>10</sup> which control the glucose metabolism and inflammation. Their action mechanism includes reduction of inflammation by lowering capillary vasodilatation and vascular permeability. This leads to reduction in the chemotaxis of polymorphonuclear cells and macrophages and reduction in the release of vasoactive kinins. Their anti-inflammatory effect is carried out by action on a nuclear receptor targeting a DNA sequence called the glucocorticoid-responsive element, helping to block the synthesis of many cytokines.<sup>11,12</sup>

### When and how

Understanding the pharmacological features of steroids can help in the choice of those to use. Triamcinolone acetonide is a corticosteroid; it is one of the least soluble corticosteroids with an extended effectiveness of about 14 days compared with 8 days of methylprednisolone acetate. Among the most used injectable steroids are methylprednisolone acetate, triamcinolone acetonide and triamcinolone hexacetonide. The methylprednisolone, which is an anti-inflammatory glucocorticoid, is usually employed for patients with rheumatic pathologies and for disturbances of the small joints. It is also used in case of acute pain owing to its quick effect on symptomatology.<sup>12,13</sup> Steroids are typically used before any other treatment when the areas to be treated present inflammation.<sup>12-16</sup> Their administration can precede infiltrative treatments of the Achilles or patellar tendons,<sup>13</sup> in the presence of inflammation of the tendon sheath.<sup>11,13</sup> They can precede an intra-articular infiltrative treatment of the knee<sup>17,18</sup> and hip, if there is joint effusion.<sup>19-21</sup> In the shoulder, they can also be used in case of calcific tendonitis to reduce severe pain as quickly as possible.<sup>22</sup> This kind of treatment has several limitations and/or contraindications related, for example, to the presence of patients with diabetes or allergy or professional athletes.<sup>23</sup> As for imaging, pre- and post-treatment ultrasounds and/or MRI examinations show disappearance or reduction of bursitis or peritendinous inflammation. When treating the underlying or associated diseases (tendinosis or partial lesions), however, no significant clinical and functional benefits are observed.

### Complications

The literature<sup>9,11,13,24</sup> describes rare side effects of injected corticosteroids, such as involvement of the joint (infection, steroid arthropathy and post-injection flare) and the surrounding soft tissues (asymptomatic pericapsular calcification, subcutaneous fat or skin atrophy/depigmentation and tendon rupture). Systemic effects are also described, such as facial flushing, vasovagal reaction or hypersensitivity reactions. The most feared is septic arthritis, which is extremely rare. In patients with diabetes, the control of blood glucose level is necessary in case of repeated steroid injections. An increase of blood glucose was reported in patients treated with soft tissues or peritendinous infiltrative procedure.<sup>13,24</sup> Great attention is necessary in case of patients with bacteraemia, sepsis, skin lesion at the site of the injection, coagulopathy pathologies or joint prostheses.

## PLATELET-RICH PLASMA

### Pharmacological aspects

The platelet-rich plasma (PRP) is obtained by withdrawing blood directly from the patient, with a needle of 18-20 G, to avoid trauma to the platelets, which if damaged would release their

growth factors early.<sup>25–28</sup> The syringe contains an anticoagulant (ratio of sodium citrate and blood, 1:9) in order to chelate calcium, block the coagulation cascade and preserve the growth factors. The blood is subsequently submitted for centrifugation and cell-separation processes to obtain a new substance richer in platelets. After centrifugation, a composite laminate is obtained, consisting of red blood cells, platelet-poor plasma and PRP. Usually, the volume of PRP obtained is 1/10 of the volume of the whole blood (6 ml per 60 ml of blood drawn or 3 ml per 30 ml of the fluid). Sodium bicarbonate is added (about 0.05 ml of sodium bicarbonate for each millilitre of PRP) to buffer the acidity results from platelet metabolism; an excessive pH decrease could jeopardize the viability of the platelets.<sup>26,27</sup> Once injected at the injection site, the platelets will activate when they come into contact with substances such as collagen Type I or through paracrine mechanisms related to the release of platelet-activating factors from previous elements lysed by trauma incurred during handling.<sup>28</sup> The PRP may be injected in this form after further activation with either calcium gluconate or sodium bicarbonate. The activation leads to a faster release of growth factors; the possibility of activating PRP also depends on the intended use.<sup>29</sup> The main advantages of PRP are safety (directly taken from the patient's own blood). In this way, the risk of contracting communicable diseases such as hepatitis is avoided.<sup>30</sup> Another advantage of PRP is its cost effectiveness, especially compared with the costs of producing artificial tissues. The mechanisms of action of PRP are not fully known yet, but are believed to be related to a slow continuous release of growth factors present in abundance in the platelet gel. The action mechanisms of the best-known platelet growth factors are briefly exposed below.<sup>25,28,31,32</sup>

The platelet-derived growth factor has a mitogenic action (it induces mitosis or cell replication) and induces angiogenesis; it also coordinates the action of other growth factors.

The transforming growth factor- $\beta$  is a protein with many functions, including the stimulation of osteoblasts and fibroblasts and the inhibition of osteoclasts.

The insulin-like growth factor I/II acts by stimulating the production of osteoblasts and acting on precursors of the latter; they also stimulate the deposition of the bone matrix.

The basic fibroblast growth factor works by stimulating the migration of fibroblasts and collagen synthase. It is the growth factor that plays the most interesting role in the field of aesthetic medicine.

The epidermal growth factor works by stimulating the mesenchymal and epidermal cells.

#### When and how

The growing interest in the use of blood derivatives such as PRP in the joint diseases is due to the release of the growth factors contained in platelets that have anti-inflammatory and regenerative capacity.<sup>25,27,28,33–36</sup> The use of PRP under ultrasound guidance, in the treatment of degenerative processes<sup>34</sup> and arthritic knee and hip, is efficient in terms of reduction of pain and recovery of functionality.<sup>35–39</sup> The platelet gel exerts an anti-inflammatory action related to the chemotactic activity towards

the cells of inflammation and promotes true tissue regeneration due to the activation of growth factors.<sup>40</sup> This should lead at the local level to a reduction of the inflammatory phenomena, with effects on pain, and to a partial tissue restoration. Thanks to its regenerating capacity, PRP can also be used in degenerative diseases and in case of partial tendon lesions. In these cases, it is injected directly into the tendon structure<sup>41,42</sup> in a single site (in case of partial lesions) or in multiple locations of the tendon in case of diffuse degeneration.<sup>43</sup> Usually, in clinical practice, PRP is used for tendinosis or partial lesions of tendons such as supraspinatus<sup>41,44</sup> (Figure 1), Achilles tendons<sup>45</sup> and patellar tendons<sup>46–48</sup> (Figure 2) or for epicondylitis,<sup>49–51</sup> sports muscle injuries<sup>52</sup> and flexor/extensor tendons of the hand.<sup>42</sup>

Patient recruitment is carried out using diagnostic imaging modalities. With them, it is possible to carry out a more accurate evaluation of arthritis or tendinopathy and to make a qualitative as well as quantitative comparison before and after the treatment.<sup>41–44,46,53</sup>

#### Complications

Sometimes, pain after treatment was observed, but it responded to analgesics or systemic anti-inflammatories. Possible side effects of PRP injection treatments are divided into absolute and relative. The first group includes septic arthritis, overlying cellulitis, adjacent osteomyelitis, haemodynamic instability or septicemia, critical thrombocytopenia, platelet dysfunction syndrome and cancer (mostly haematopoietic or bone cancer). Other complications are allergic reactions, skin discolouration or blood clots. Some authors describe adhesive capsulitis and tendon rupture, in case of intratendinous injection.<sup>37,38,41–43,45,47,49,52,54</sup>

## HYALURONIC ACID

### Pharmacological aspect

Hyaluronic acid (HA) is a glycosaminoglycan, one of the main components of the extracellular matrix. It is a polymer of high molecular weight (several million Dalton), consisting of units of glucuronic acid and *N*-acetylglucosamine bound together by glycosidic bridges. It is produced by synovial cells of Type B and fibroblasts through HA synthase and is then released into the synovial fluid. Its catabolism takes place in the synovial fluid by hyaluronidase. HA has viscoelastic properties; it allows lubrication, regulates the permeability to nutrients and protects the tissue by inflammatory cells.<sup>55</sup>

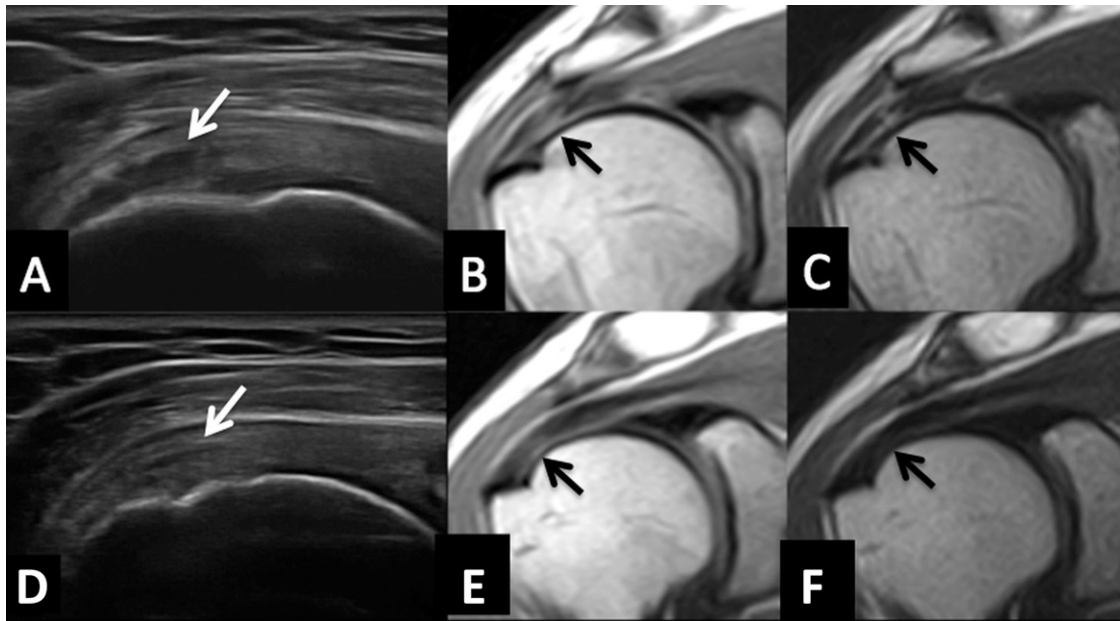
### When and how

The exact mechanism of action of exogenous HA is not known, but it seems that it may act through a dual mechanism:

- direct mechanical protection of the joint surface through the articular surface
- indirectly through many metabolic effects, including the induction of endogenous HA production (viscoinduction), the reduction of the presence of inflammatory cells in the synovial fluid and the possible stimulation of the proliferation and differentiation of chondrocytes.

The mechanism of action of exogenous HA is greatly influenced by its molecular weight: the biological activity prevails in the low/average molecular weight while the rheological and analgesic activities prevail in the high molecular weight. HA for

Figure 1. The top image on the left (a) is showing the hypoechoic focal area of tendinopathy at the level of the insertional portion of the supraspinatus tendon (white arrow); in the middle (b) and on the right (c),  $T_1$  and  $T_2$  weighted images of the same lesion (black arrows) are shown. The bottom images report the good results obtained after platelet-rich plasma treatment at both the ultrasound (d) and MRI (e, f) examinations with the reduction of the lesion [white arrow in (d) and black arrows in (e, f)].



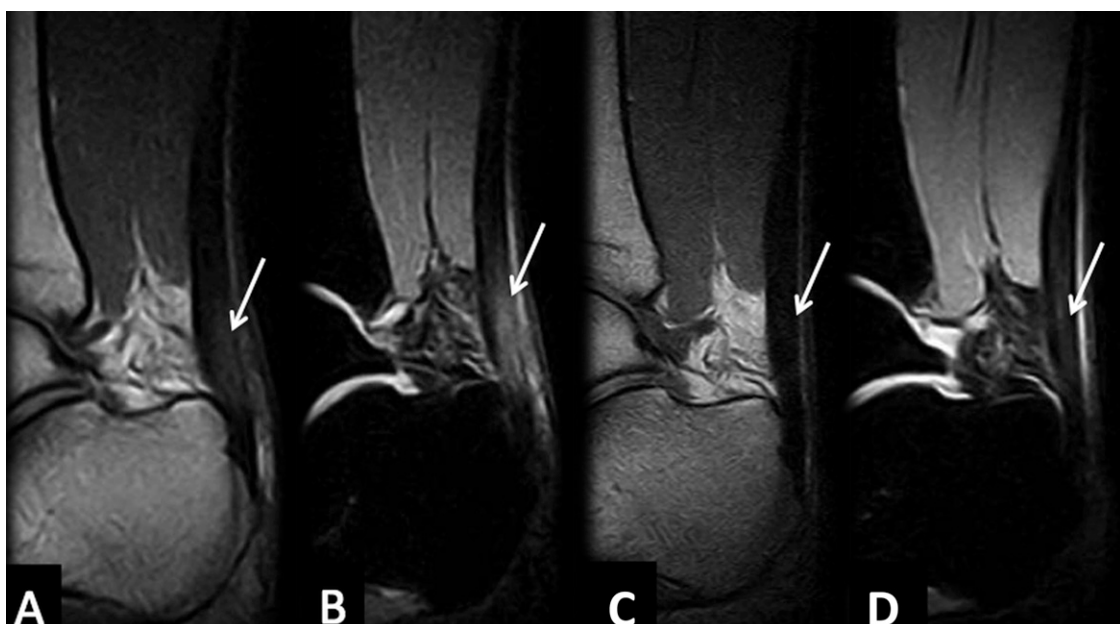
intra-articular use is produced in two ways: bacterial fermentation and purification, and extraction and purification from rooster combs. The products thus obtained can be modified by cross-linking to increase the molecular weight of the product. The differences in the technique of production result in a different molecular weight of the product and, according to some authors,<sup>35,55,56</sup> even in a different clinical efficacy. Some authors

have attributed the greater clinical effect to the HA of a high molecular weight on the basis of *in vitro* studies; but, the heterogeneity of the results do not allow precise statements about it.<sup>35,55,56</sup>

#### Complications

Despite the commercial products finding wide use, clinical studies have shown that in some cases (from 1 to 11% of cases),

Figure 2. The sagittal plane on the  $T_1$  (a) and STIR (b) images demonstrate Achilles tendinopathy at the level of the insertional area (white arrows); the sagittal plane on the  $T_1$  (c) and STIR (d) images are showing the results after platelet-rich plasma treatment with reduction of the thickness of this area (white arrows).



in the 24–48 h following the intervention of viscosupplementation, the patient develops inflammatory reactions with the appearance of transient pain in the interested articulation, swelling and erythema. It has not been established what are the causes of such post-injection synovitis that does not occur frequently after the first surgery, but whose frequency increases considerably after the second injection and in subsequent cycles. Some authors<sup>35,55,56</sup> attribute it to the injection technique, but there is no evidence to support this claim; it is more likely that it depends on the foreign body reaction or hypersensitivity to certain protein components present in the product injected. Systemic effects related to the administration of HA have rarely emerged and are represented by rash, hives, itching, fever, nausea, headache, dizziness, chills, muscle cramps, paraesthesia, peripheral oedema, face oedema and malaise. HA should not be used in patients with known hypersensitivity and in the presence of severe infections, inflammations or skin diseases. It should not be used if there is articular joint effusion or in the presence of venous stasis.<sup>35,55,56</sup>

### OXYGEN-OZONE

The oxygen–ozone (O<sub>2</sub>–O<sub>3</sub>) therapy is based on the application of a mixture of 97% of medical oxygen (O<sub>2</sub>) and 3% ozone (O<sub>3</sub>). Ozone is an inorganic molecule, discovered in 1832 by Christian Friedrich Schönbein. He described the strong odour during the slow oxidation experiments of white phosphorus and the electrolysis of water, and, in 1839, he named this molecule ozone. In 1857, von Siemens demonstrated that ozone can be produced by the passage of oxygen through an electric arc, thus building the first ozone generator. Ozone is found in large quantities in the atmosphere, about 25 km from the earth surface, where it is able to absorb ultraviolet rays from the sun, protecting this planet from their harmful action. Minor amounts of ozone are also present in the lower atmosphere (ozone is an essential component of smog), but this type of ground-level ozone is a pollutant and can be poisonous if inhaled in large doses.<sup>57</sup> Ozone is highly unstable: in gaseous form at 20 °C, its half-life is 3 days, while in liquid form, in addition to being an explosive, its half-life is 20 min. This means that it cannot be stored but must be produced just before use. It is produced by an endothermic reaction of oxygen molecules in the vicinity of an electric shock and lightning through the reaction  $3\text{O}_2 \rightarrow 2\text{O}_3$ .<sup>57</sup>

#### When and how

Ozone is used in both the industry and medical field and in the latter case, it is used after being mixed with oxygen (constituting the medical ozone O<sub>2</sub>–O<sub>3</sub>). The ozone therapy is being practised since World War I, when it was applied to wounds in order to avoid amputation for gangrene; but, only in recent years, more detailed studies have appeared on its effect. The systems currently used for the production of ozone are based on the patent of an ozone generator, now known as the “Siemens Type” generator, designed by Werner von Siemens in 1857. Welsbach, in fact, used cells made of two concentric electrodes separated by a gap of a few fractions of a millimetre (about 0.5–0.8 mm) through which oxygen passes. The two electrodes have a voltage difference of about 7–30 kV. The internal metallic electrode is connected to a medium voltage generator, while the external electrode, which is made of glass or ceramic, is connected to the

ground. There is also a cooling system that removes the heat generated by the reaction of medical ozone formation. The voltage difference between the two electrodes allows splitting of oxygen molecules and the formation of ozone molecules. After the production, the mixture of oxygen–ozone is conveyed towards two routes; the first available to the operator with the aid of a syringe. The second route, however, destroys the unused mixture. Ozone is a strong irritant gas, is colourless, oxidizes, is more reactive than oxygen and is able to split unsaturated substances, forming the reactive oxygen species. If the oxidative stress lasts for a short time, the antioxidant systems of the body fail to lock it by the activation of glutathione, superoxide dismutase *etc.* with detoxifying action. If the oxidative stress persists owing to chronic conditions or in the presence of antioxidant system deficits, it causes cellular damage. Ozone plays an analgesic and anti-inflammatory action through the inhibition of cyclooxygenase, stimulation of the metabolism of histamine and monoamine oxidase with reduction of vasodilation and muscle hypertonicity. The medical ozone determines the increase of glycolysis, lipolysis and platelet reduction increasing the blood concentration of 2,3-bisphosphoglycerate (2,3DPG), which results in eutrophic, anti-inflammatory and analgesic effects, with greater flow of blood and oxygen to the tissues. Through stimulation of production and release of cytokines and interferons, it has immunomodulatory effects. Actually, the typical way to use ozone is chemiodiscolysis: in fact, the use of ozone therapy is a treatment option that is used to treat intervertebral disc extrusion where conservative therapies and/or surgery are not indicated. O<sub>2</sub>–O<sub>3</sub> is rarely injected at the level of the joint or in the tendons, and the therapeutic effects are similar if not lower than those obtained using other drugs such as steroids. There are no contraindications to the use of ozone; but, attention must be paid to some patient conditions such as pregnancy, hyperthyroidism, severe cardiovascular diseases and heart failure.<sup>57–59</sup>

#### Complications

Among the side effects of ozone, the effects based on the O<sub>2</sub>–O<sub>3</sub> mixture must be distinguished from those based on the administration technique. Among the first, a spectrum of situations can be observed, ranging from the simple feeling of heaviness or burning at the injection site to a real vagal crisis. Among the adverse effects based on the technique of administration, there can be lesions created by the needle during its penetration: haematoma, injury to small blood vessels, pain and sensitivity disorders in the nerve roots and discitis due to a non-sterile procedure. All these events, however, are rare and can be avoided through compliance with good procedures.<sup>59</sup>

### OTHER DRUGS AND AGENTS USED

#### Prolotherapy

It consists in injecting hyperosmolar dextrose into the area of tendinosis.<sup>60</sup> Dextrose is an irritant drug which may act in two ways to relieve pain: causing inflammation with the release of growth factors, or creating tissue regeneration acting as a sclerosing factor to vascular tissue.<sup>61</sup>

#### Whole blood

It is obtained directly from the patient. Peripheral blood is taken from the patient and reinjected into the pathologic tendon.

Platelets contained in autologous blood can increase the release of growth factors at the injection site.<sup>62</sup> Compared with whole blood, PRP contains, after centrifugation, a greater concentration of platelets and induces more rapid release of growth factors. However, this is still the subject of studies. Both types of injections are often combined with needling.<sup>63,64</sup>

#### Tendon fenestration or needling

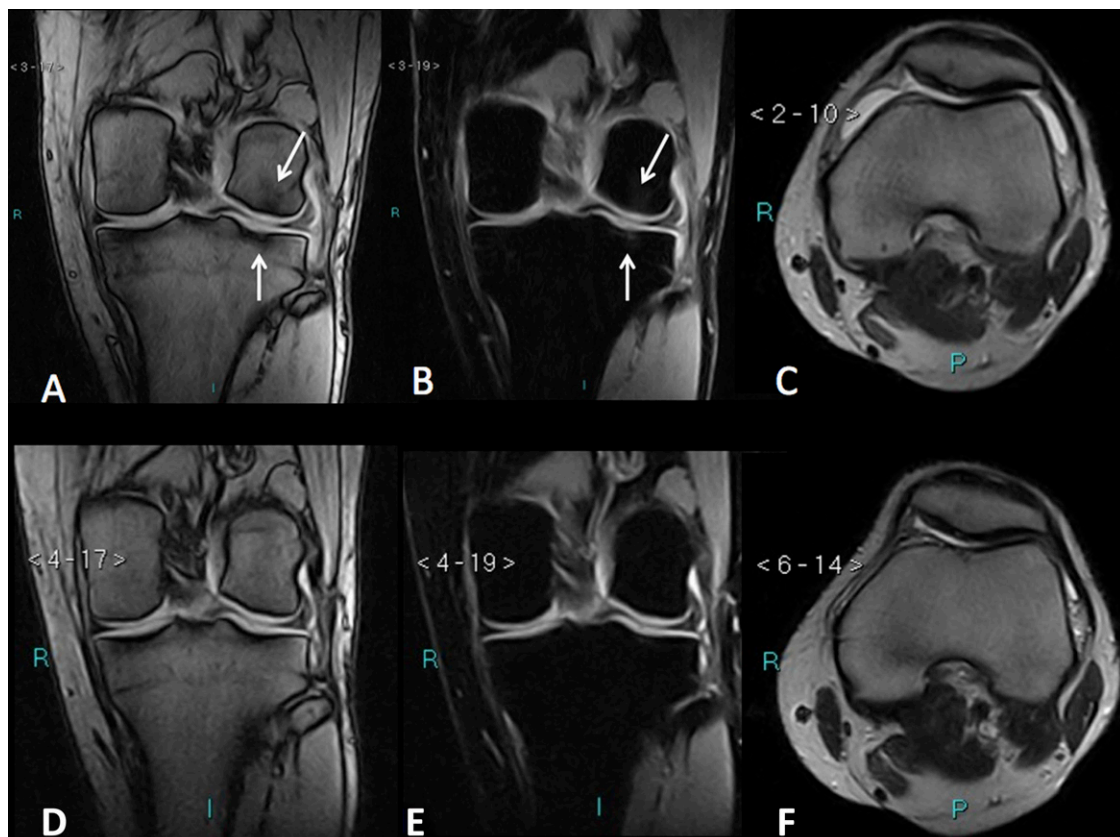
It consists in inserting a needle into the pathological area, without injecting drugs. Also in this case, the use of an ultrasound probe is necessary to ensure the proper placement of the needle at the level of the area to be treated without puncturing adjacent structures. This technique consists in repeatedly introducing a needle into the diseased area, creating a bleeding at that level of the tendon structure and inducing an inflammation with the release of growth factors and other substances, which stimulate the process of healing. In literature, there are many studies describing this technique as effective in the treatment of epicondylitis, and also in the treatment of the patellar and Achilles tendons diseases.<sup>65</sup>

#### DISCUSSION AND CONCLUSION

Diagnostic imaging modalities have proven to be very useful in clinical practice to evaluate a wide range of musculoskeletal pathologies.<sup>66-77</sup> The use of diagnostic imaging techniques such as ultrasound, CT and MRI to guide or to verify the

effect of musculoskeletal intervention is also widespread.<sup>78-82</sup> Infiltrative therapies employed in interventional musculoskeletal radiology are very effective and versatile clinical therapeutic tools.<sup>1,2,4,8,9,25,34,43,56</sup> The drugs for US-guided infiltrative therapy have been used since the beginning of the twentieth century, but they have also been used in previous years in many different fields of medicine such as orthopaedics, rheumatology, physiatrics *etc.*<sup>25,32,34,43,56</sup> Until a few years ago, owing to poor availability and poor knowledge of pharmacological effects, only a few drugs (anaesthetics and steroids)<sup>5,8,9</sup> were used. New imaging technologies, advancements in diagnostic equipment and knowledge of joint diseases in addition to the discovery and introduction of new drugs (HA and PRP)<sup>27,34,35,37,41,43,52,55</sup> in the past years have enabled the development of a modern discipline that combines knowledge and technology for the treatment of joint diseases. Currently, a broader field of action is possible in the field of musculoskeletal pathologies whose treatment was unthinkable only a few years ago. Aided by imaging, it is possible to accurately achieve the site to be treated with a small margin of error, following in real time every step of the procedure. The availability of a variety of new drugs provides expansion of the indications and therapeutic possibilities, with resolution of pain and maximum therapeutic outcome. The patient comes for observation, is submitted to clinical examination with assessment of pain and function and subsequently undergoes ultrasound scan and MR for a proper assessment of

Figure 3. In the  $T_1$  weighted image (a) and the STIR image (b), the coronal planes are showing the femoral and tibial chondral damages (white arrows) on the lateral side, with joint effusion in the anterior recess on the axial plane (c). After platelet-rich plasma treatment, the coronal MR images are demonstrating the disappearance of the chondral damages in (d, e) (coronal planes) and the reduction of the joint effusion in (f) (axial plane).



the joint pathology. In most cases, pain is related to an inflammatory process secondary to the underlying disease. The patient is initially treated with steroids to reduce inflammation. Steroids can be injected only into the recess joint or the tendon bursa but not directly into the tendon structures or into the muscle. McCabe et al,<sup>83</sup> in a recent review, reported a reduction in pain after steroid injection at 3–4 weeks post-treatment in all cases, with a marked reduction after 1 week; they also put attention on the effectiveness of the steroid treatment, but emphasized on the poor quality of the evidence reported. Once inflammation is resolved, treatment of the underlying disease can start. In a randomized trial, Sun et al<sup>5</sup> demonstrated that patients treated with systemic non-steroidal anti-inflammatory drugs did not obtain results for pain relief and functional improvement. Over the past few years, the use of blood derivatives has become increasingly important in the treatment of musculoskeletal diseases. Significant results have been obtained with the *in situ* application of PRP to induce tissue regeneration in degenerative diseases affecting the joints and tendons. Good results are described in literature regarding the use of PRP in the treatment of degenerative tendon diseases,<sup>1,33,34,37,38,43</sup> such as rotator cuff tendinosis<sup>41–44</sup> or plantar fasciitis, and in particular the insertional tendon disease of the Achilles<sup>45</sup> and patellar tendons.<sup>46–48</sup> Wilson et al<sup>84</sup> evaluated, after PRP intratendinous injection, the intratendinous retention and distribution of the

injected substance, tissue morphology following injection and effect of intratendinous injection and fenestration, demonstrating how PRP is not only feasible but also remains in the tendon after the procedure with slight loss outside the tendon. In another study, Wesner et al<sup>85</sup> observed that patients treated with PRP for degenerative tendinopathies obtained clinical efficacy and improvement of tendon lesions at MRI compared with the control group. Some authors also focus on the importance of employing PRP in the treatment of osteoarthritis of the knee<sup>31,34,35,37,38,40</sup> to reduce joint inflammation and to delay degenerative processes of the cartilage (Figure 3). These results are also reported by Meheux et al,<sup>86</sup> who described differences in terms of pain, stiffness and physical function, comparing patients treated with PRP with those treated with HA.

In conclusion, on the basis of critical literature review, the clinical data considered in terms of reduction of pain, functional recovery and morphological recovery suggest that the use of steroids in combination with PRP may be a good therapeutic alternative treatment in tendon and extremity joint degenerative and inflammatory diseases.

#### ACKNOWLEDGMENTS

The authors wish to thank Angela Martella for translation of the article.

#### REFERENCES

- Smith J, Finnoff JT. Diagnostic and interventional musculoskeletal ultrasound: part 2. Clinical applications. *PM R* 2009; **1**: 162–77. doi: <http://dx.doi.org/10.1016/j.pmrj.2008.09.002>
- del Cura JL. Ultrasound-guided therapeutic procedures in the musculoskeletal system. *Curr Probl Diagn Radiol* 2008; **37**: 203–18. doi: <http://dx.doi.org/10.1067/j.cpradiol.2007.08.001>
- Caudana R, Genovese E, Masciocchi C. *Musculoskeletal Interventional Radiology*. Masson, Italy: Elsevier; 2011.
- Adler RS, Sofka CM. Percutaneous ultrasound-guided injections in the musculoskeletal system. *Ultrasound Q* 2003; **19**: 3–12. doi: <http://dx.doi.org/10.1097/00013644-200303000-00002>
- Sun QB, Liu SD, Meng QJ, Qu HZ, Zhang Z. Single administration of intra-articular bupivacaine in arthroscopic knee surgery: a systematic review and meta-analysis. *BMC Musculoskelet Disord* 2015; **16**: 21. doi: <http://dx.doi.org/10.1186/s12891-015-0477-6>
- Gorrell RL. Procaine injections for painful musculoskeletal conditions: a fifteen-year follow-up. *J Lancet* 1955; **75**: 32–7.
- Leveaux VM, Quin CE. Local injection of hydrocortisone and procaine in osteoarthritis of the hip joint. *Ann Rheum Dis* 1956; **15**: 330–7. doi: <http://dx.doi.org/10.1136/ard.15.4.330>
- Mosshammer D, Mayer B, Joos S. Local anesthetics injection therapy for musculoskeletal disorders: a systematic review and meta-analysis. *Clin J Pain* 2013; **29**: 540–50. doi: <http://dx.doi.org/10.1097/AJP.0b013e318261a474>
- Habib GS, Saliba W, Nashashibi M. Local effects of intra-articular corticosteroids. *Clin Rheumatol* 2010; **29**: 347–56. doi: <http://dx.doi.org/10.1007/s10067-009-1357-y>
- Menon N, Kothari SY, Gogna A, Sharma R. Comparison of intra-articular glucocorticoid injections with DMARDs versus DMARDs alone in rheumatoid arthritis. *J Assoc Physicians India* 2014; **62**: 673–6.
- Eyigor C, Eyigor S, Kivilcim Korkmaz O. Are intra-articular corticosteroid injections better than conventional TENS in treatment of rotator cuff tendinitis in the short run? A randomized study. *Eur J Phys Rehabil Med* 2010; **46**: 315–24.
- Bannuru RR, Schmid CH, Kent DM, Vaysbrot EE, Wong JB, McAlindon TE, et al. Comparative effectiveness of pharmacologic interventions for knee osteoarthritis: a systematic review and network meta-analysis. *Ann Intern Med* 2015; **162**: 46–54. doi: <http://dx.doi.org/10.7326/M14-1231>
- Stephens MB, Beutler AI, O'Connor FG. Musculoskeletal injections: a review of the evidence. *Am Fam Physician* 2008; **78**: 971–6.
- Vitale MA. Doc, will this injection make my trigger finger go away? Commentary on an article by Robert D. Wojahn, MD, et al.: “Long-term outcomes following a single corticosteroid injection for trigger finger”. *J Bone Joint Surg Am* 2014; **96**: e191. doi: <http://dx.doi.org/10.2106/JBJS.N.00832>
- Krogh TP, Fredberg U, Stengaard-Pedersen K, Christensen R, Jensen P, Ellingsen T. Treatment of lateral epicondylitis with platelet-rich plasma, glucocorticoid, or saline: a randomized, double-blind, placebo-controlled trial. *Am J Sports Med* 2013; **41**: 625–35. doi: <http://dx.doi.org/10.1177/0363546512472975>
- Cecen GS, Gulabi D, Saglam F, Tanju NU, Bekler HI. Corticosteroid injection for trigger finger: blinded or ultrasound-guided injection? *Arch Orthop Trauma Surg* 2015; **135**: 125–31. doi: <http://dx.doi.org/10.1007/s00402-014-2110-9>
- Henriksen M, Christensen R, Klokke L, Bartholdy C, Bandak E, Ellegaard K, et al. Evaluation of the benefit of corticosteroid injection before exercise therapy in patients with osteoarthritis of the knee: a randomized clinical trial. *JAMA Intern Med* 2015; **175**:



- 923–30. doi: <http://dx.doi.org/10.1001/jamainternmed.2015.0461>
18. Tresley J, Jose J. Sonographically guided posteromedial approach for intra-articular knee injections: a safe, accurate, and efficient method. *J Ultrasound Med* 2015; **34**: 721–6. doi: <http://dx.doi.org/10.7863/ultra.34.4.721>
  19. Dobson MM. A further anatomical check on the accuracy of intra-articular hip injections in relation to the therapy of coxarthrosis. *Ann Rheum Dis* 1950; **9**: 237–40. doi: <http://dx.doi.org/10.1136/ard.9.3.237>
  20. Crowe HW. Osteo-arthritis of the hip-joint treated by intra-articular injections. *Proc R Soc Med* 1947; **40**: 486–7.
  21. Anderson ES, Hodel E, Mantuani D, Fahimi J, Pampalone I, Nagdev A. Pilot study of ultrasound-guided corticosteroid hip injections by emergency physicians. *West J Emerg Med* 2014; **15**: 919–24. doi: <http://dx.doi.org/10.5811/westjem.2014.9.20575>
  22. Rhon DI, Boyles RB, Cleland JA. One-year outcome of subacromial corticosteroid injection compared with manual physical therapy for the management of the unilateral shoulder impingement syndrome: a pragmatic randomized trial. *Ann Intern Med* 2014; **161**: 161–9. doi: <http://dx.doi.org/10.7326/M13-2199>
  23. Scott WA. Injection techniques and use in the treatment of sports injuries. *Sports Med* 1996; **22**: 406–16. doi: <http://dx.doi.org/10.2165/00007256-199622060-00007>
  24. Baker K, O'Rourke KS, Deodhar A. Joint aspiration and injection: a look at the basics. *Rheumatology network*; 2011.
  25. Ramos-Torrecillas J, De Luna-Bertos E, García-Martínez O, Ruiz C. Clinical utility of growth factors and platelet-rich plasma in tissue regeneration: a review. *Wounds* 2014; **26**: 207–13.
  26. Sabarish R, Lavu V, Rao SR. A comparison of platelet count and enrichment percentages in the platelet rich plasma (prp) obtained following preparation by three different methods. *J Clin Diagn Res* 2015; **9**: ZC10–2. doi: <http://dx.doi.org/10.7860/JCDR/2015/11011.5536>
  27. Dhurat R, Sukesh M. Principles and methods of preparation of platelet-rich plasma: a review and author's perspective. *J Cutan Aesthet Surg* 2014; **7**: 189–97. doi: <http://dx.doi.org/10.4103/0974-2077.150734>
  28. Krüger JP, Hondke S, Endres M, Pruss A, Siclari A, Kaps C. Human platelet-rich plasma stimulates migration and chondrogenic differentiation of human subchondral progenitor cells. *J Orthop Res* 2012; **30**: 845–52. doi: <http://dx.doi.org/10.1002/jor.22005>
  29. Plöderl K, Strasser C, Hennerbichler S, Peterbauer-Scherb A, Gabriel C. Development and validation of a production process of platelet lysate for autologous use. *Platelets* 2011; **22**: 204–9. doi: <http://dx.doi.org/10.3109/09537104.2010.531304>
  30. Schmolz M, Stein GM, Hubner WD. An innovative, centrifugation-free method to prepare human platelet mediator concentrates showing activities comparable to platelet-rich plasma. *Wounds* 2011; **23**: 171–82.
  31. Akeda K, An HS, Okuma M, Attawia M, Miyamoto K, Thonar EJ, et al. Platelet-rich plasma stimulates porcine articular chondrocyte proliferation and matrix biosynthesis. *Osteoarthritis Cartilage* 2006; **14**: 1272–80. doi: <http://dx.doi.org/10.1016/j.joca.2006.05.008>
  32. Landesberg R, Roy M, Glickman RS. Quantification of growth factor levels using a simplified method of platelet-rich plasma gel preparation. *J Oral Maxillofac Surg* 2000; **58**: 297–300; discussion 300–1. doi: [http://dx.doi.org/10.1016/S0278-2391\(00\)90058-2](http://dx.doi.org/10.1016/S0278-2391(00)90058-2)
  33. Diiorio TM, Burkholder JD, Good RP, Parvizi J, Sharkey PE. Platelet-rich plasma does not reduce blood loss or pain or improve range of motion after TKA. *Clin Orthop Relat Res* 2012; **470**: 138–43. doi: <http://dx.doi.org/10.1007/s11999-011-1972-1>
  34. Lai LP, Stitik TP, Foye PM, Georgy JS, Patibanda V, Chen B. Use of platelet-rich plasma in intra-articular knee injections for osteoarthritis: a systematic review. *PM R* 2015; **7**: 637–48. doi: <http://dx.doi.org/10.1016/j.pmrj.2015.02.003>
  35. Raieissadat SA, Rayegani SM, Hassanabadi H, Fathi M, Ghorbani E, Babaei M, et al. Knee osteoarthritis injection choices: platelet-rich plasma (PRP) versus hyaluronic acid (a one-year randomized clinical trial). *Clin Med Insights Arthritis Musculoskelet Disord* 2015; **8**: 1–8. doi: <http://dx.doi.org/10.4137/CMAMD.S17894>
  36. Wei LC, Gao SG, Xu M, Jiang W, Tian J, Lei GH. A novel hypothesis: the application of platelet-rich plasma can promote the clinical healing of white-white meniscal tears. *Med Sci Monit* 2012; **18**: HY47–50. doi: <http://dx.doi.org/10.12659/MSM.883254>
  37. Rodriguez-Merchan EC. Intraarticular injections of platelet-rich plasma (PRP) in the management of knee osteoarthritis. *Arch Bone Jt Surg* 2013; **1**: 5–8.
  38. Sánchez M, Guadilla J, Fiz N, Andia I. Ultrasound-guided platelet-rich plasma injections for the treatment of osteoarthritis of the hip. *Rheumatology (Oxford)* 2012; **51**: 144–50. doi: <http://dx.doi.org/10.1093/rheumatology/ker303>
  39. Xie X, Ulici V, Alexander PG, Jiang Y, Zhang C, Tuan RS, et al. Platelet-rich plasma inhibits mechanically induced injury in chondrocytes. *Arthroscopy* 2015; **31**: 1142–50. doi: <http://dx.doi.org/10.1016/j.arthro.2015.01.007>
  40. Sakata R, McNary SM, Miyatake K, Lee CA, Van den Bogernde JM, Marder RA, et al. Stimulation of the superficial zone protein and lubrication in the articular cartilage by human platelet-rich plasma. *Am J Sports Med* 2015; **43**: 1467–73. doi: <http://dx.doi.org/10.1177/0363546515575023>
  41. Malavolta EA, Gracitelli ME, Ferreira Neto AA, Assunção JH, Bordalo-Rodrigues M, de Camargo OP. Platelet-rich plasma in rotator cuff repair: a prospective randomized study. *Am J Sports Med* 2014; **42**: 2446–54. doi: <http://dx.doi.org/10.1177/0363546514541777>
  42. Andia I, Latorre PM, Gomez MC, Burgos-Alonso N, Abate M, Maffulli N. Platelet-rich plasma in the conservative treatment of painful tendinopathy: a systematic review and meta-analysis of controlled studies. *Br Med Bull* 2014; **110**: 99–115. doi: <http://dx.doi.org/10.1093/bmb/ldu007>
  43. Lubowitz JH, Poehling GG. Shoulder, hip, knee, and PRP. *Arthroscopy* 2010; **26**: 141–2. doi: <http://dx.doi.org/10.1016/j.arthro.2009.12.005>
  44. Wang A, McCann P, Colliver J, Koh E, Ackland T, Joss B, et al. Do postoperative platelet-rich plasma injections accelerate early tendon healing and functional recovery after arthroscopic supraspinatus repair? A randomized controlled trial. *Am J Sports Med* 2015; **43**: 1430–7. doi: <http://dx.doi.org/10.1177/0363546515572602>
  45. Gaweda K, Tarczynska M, Krzyzanowski W. Treatment of Achilles tendinopathy with platelet-rich plasma. *Int J Sports Med* 2010; **31**: 577–83. doi: <http://dx.doi.org/10.1055/s-0030-1255028>
  46. Drago JL, Wasterlain AS, Braun HJ, Nead KT. Platelet-rich plasma as a treatment for patellar tendinopathy: a double-blind, randomized controlled trial. *Am J Sports Med* 2014; **42**: 610–8. doi: <http://dx.doi.org/10.1177/0363546513518416>
  47. Andia I, Maffulli N. Use of platelet-rich plasma for patellar tendon and medial collateral ligament injuries: best current clinical practice. *J Knee Surg* 2015; **28**: 11–8. doi: <http://dx.doi.org/10.1055/s-0034-1384671>
  48. Kon E, Filardo G, Delcogliano M, Presti ML, Russo A, Bondi A, et al. Platelet-rich plasma: new clinical application: a pilot study for treatment of jumper's knee. *Injury* 2009; **40**: 598–603. doi: <http://dx.doi.org/10.1016/j.injury.2008.11.026>

49. Friedlander HL, Reid RL, Cape RF. Tennis elbow. *Clin Orthop Relat Res* 1967; **51**: 109–16.
50. Ahmad Z, Brooks R, Kang SN, Weaver H, Nunney I, Tytherleigh-Strong G, et al. The effect of platelet-rich plasma on clinical outcomes in lateral epicondylitis. *Arthroscopy* 2013; **29**: 1851–62. doi: <http://dx.doi.org/10.1016/j.arthro.2013.07.272>
51. Mishra A, Pavelko T. Treatment of chronic elbow tendinosis with buffered platelet-rich plasma. *Am J Sports Med* 2006; **34**: 1774–8.
52. Andia I, Sánchez M, Maffulli N. Platelet rich plasma therapies for sports muscle injuries: any evidence behind clinical practice? *Expert Opin Biol Ther* 2011; **11**: 509–18. doi: <http://dx.doi.org/10.1517/14712598.2011.554813>
53. Gobbi A, Lad D, Karnatzikos G. The effects of repeated intra-articular PRP injections on clinical outcomes of early osteoarthritis of the knee. *Knee Surg Sports Traumatol Arthrosc* 2015; **23**: 2170–7. doi: <http://dx.doi.org/10.1007/s00167-014-2987-4>
54. Kaux JF, Croisier JL, Léonard P, Le Goff C, Crielaard JM. Exuberant inflammatory reaction as a side effect of platelet-rich plasma injection in treating one case of tendinopathy. *Clin J Sport Med* 2014; **24**: 150–2. doi: <http://dx.doi.org/10.1097/JSM.0b013e31829aa410>
55. McArthur BA, Dy CJ, Fabricant PD, Valle AG. Long term safety, efficacy, and patient acceptability of hyaluronic acid injection in patients with painful osteoarthritis of the knee. *Patient Prefer Adherence* 2012; **6**: 905–10. doi: <http://dx.doi.org/10.2147/PPA.S27783>
56. Rutjes AW, Jüni P, da Costa BR, Trelle S, Nuesch E, Reichenbach S. Viscosupplementation for osteoarthritis of the knee: a systematic review and meta-analysis. *Ann Intern Med* 2012; **157**: 180–91. doi: <http://dx.doi.org/10.7326/0003-4819-157-3-201208070-00473>
57. Splendiani A, Perri M, Conchiglia A, Fasano F, Di Egidio G, Masciocchi C, et al. MR assessment of lumbar disk herniation treated with oxygen-ozone diskolysis: the role of DWI and related ADC versus intervertebral disk volumetric analysis for detecting treatment response. *Neuroradiol J* 2013; **26**: 347–56.
58. Perri M, Grattacaso G, Di Tunno V, Marsecano C, Di Cesare E, Splendiani A, et al. MRI DWI/ADC signal predicts shrinkage of lumbar disc herniation after O2-O3 discolysis. *Neuroradiol J* 2015; **28**: 198–204.
59. Perri M, Grattacaso G, Di Tunno V, Marsecano C, Gennarelli A, Michelini G, et al. T2 shine-through phenomena in diffusion-weighted MR imaging of lumbar discs after oxygen-ozone discolysis: a randomized, double-blind trial with steroid and O2-O3 discolysis versus steroid only. *Radiol Med* 2015; **120**: 941–50.
60. Distel LM, Best TM. Prolotherapy: a clinical review of its role in treating chronic musculoskeletal pain. *PM R* 2011; **3**(6 Suppl. 1): S78–81. doi: <http://dx.doi.org/10.1016/j.pmrj.2011.04.003>
61. Maxwell NJ, Ryan MB, Taunton JE, Gillies JH, Wong A. Sonographically guided intra-tendinous injection of hyperosmolar dextrose to treat chronic tendinosis of the Achilles tendon: a pilot study. *AJR Am J Roentgenol* 2007; **189**: W215–20. doi: <http://dx.doi.org/10.2214/AJR.06.1158>
62. Kampa RJ, Connell DA. Treatment of tendinopathy: is there a role for autologous whole blood and platelet rich plasma injection? *Int J Clin Pract* 2010; **64**: 1813–23. doi: <http://dx.doi.org/10.1111/j.1742-1241.2010.02432.x>
63. Sheth U, Simunovic N, Klein G, Fu F, Einhorn TA, Schemitsch E, et al. Efficacy of autologous platelet-rich plasma use for orthopaedic indications: a meta-analysis. *J Bone Joint Surg Am* 2012; **94**: 298–307. doi: <http://dx.doi.org/10.2106/JBJS.K.00154>
64. Thanasas C, Papadimitriou G, Charalambidis C, Paraskevopoulos I, Papanikolaou A. Platelet-rich plasma versus autologous whole blood for the treatment of chronic lateral elbow epicondylitis: a randomized controlled clinical trial. *Am J Sports Med* 2011; **39**: 2130–4. doi: <http://dx.doi.org/10.1177/0363546511417113>
65. Chiavaras MM, Jacobson JA. Ultrasound-guided tendon fenestration. *Semin Musculoskelet Radiol* 2013; **17**: 85–90. doi: <http://dx.doi.org/10.1055/s-0033-1333942>
66. Barile A, Regis G, Masi R, Maggiori M, Gallo A, Faletti C, et al. Musculoskeletal tumours: preliminary experience with perfusion MRI. *Radiol Med* 2007; **112**: 550–61. doi: <http://dx.doi.org/10.1007/s11547-007-0161-5>
67. Karnik AS, Karnik A, Joshi A. Ultrasound examination of pediatric musculoskeletal diseases and neonatal spine. *Indian J Pediatr* 2016; **83**: 565–77. doi: <http://dx.doi.org/10.1007/s12098-015-1957-2>
68. Limbucci N, Rossi F, Salvati F, Pistoia LM, Barile A, Masciocchi C. Bilateral suprascapular nerve entrapment by glenoid labral cysts associated with rotator cuff damage and posterior instability in an amateur weightlifter. *J Sports Med Phys Fitness* 2010; **50**: 64–7.
69. Kumar Y, Khaleel M, Boothe E, Awdeh H, Wadhwa V, Chhabra A. Role of diffusion weighted imaging in musculoskeletal infections: current perspectives. *Eur Radiol* 2016. Epub ahead of print. doi: <http://dx.doi.org/10.1007/s00330-016-4372-9>
70. Masciocchi C, Lanni G, Conti L, Conchiglia A, Fascetti E, Flamini S, et al. Soft-tissue inflammatory myofibroblastic tumors (IMTs) of the limbs: potential and limits of diagnostic imaging. *Skeletal Radiol* 2012; **41**: 643–9. doi: <http://dx.doi.org/10.1007/s00256-011-1263-7>
71. Fox MG, Graham JA, Skelton BW, Blount KJ, Alford BA, Patrie JT, et al. Prospective evaluation of agreement and accuracy in the diagnosis of meniscal tears: MR arthrography a short time after injection versus CT arthrography after a moderate delay. *AJR Am J Roentgenol* 2016; **207**: 142–9.
72. Barile A, Lanni G, Conti L, Mariani S, Calvisi V, Castagna A, et al. Lesions of the biceps pulley as cause of anterosuperior impingement of the shoulder in the athlete: potentials and limits of MR arthrography compared with arthroscopy. *Radiol Med* 2013; **118**: 112–22. doi: <http://dx.doi.org/10.1007/s11547-012-0838-2>
73. Kumar Y, Wadhwa V, Phillips L, Pezeshk P, Chhabra A. MR imaging of skeletal muscle signal alterations: systematic approach to evaluation. *Eur J Radiol* 2016; **85**: 922–35. doi: <http://dx.doi.org/10.1016/j.ejrad.2016.02.007>
74. Barile A, Conti L, Lanni G, Calvisi V, Masciocchi C. Evaluation of medial meniscus tears and meniscal stability: weight-bearing MRI vs arthroscopy. *Eur J Radiol* 2013; **82**: 633–9. doi: <http://dx.doi.org/10.1016/j.ejrad.2012.10.018>
75. Kompel A, Murakami A, Guermazi A. Magnetic resonance imaging of nontraumatic musculoskeletal emergencies. *Magn Reson Imaging Clin N Am* 2016; **24**: 369–89. doi: <http://dx.doi.org/10.1016/j.mric.2015.11.005>
76. Mariani S, La Marra A, Arrigoni F, Necozone S, Splendiani A, Di Cesare E, et al. Dynamic measurement of patello-femoral joint alignment using weight-bearing magnetic resonance imaging (WB-MRI). *Eur J Radiol* 2015; **84**: 2571–8. doi: <http://dx.doi.org/10.1016/j.ejrad.2015.09.017>
77. Solivetti FM, Guerrisi A, Salduca N, Desiderio F, Graceffa D, Capodici G, et al. Appropriateness of knee MRI prescriptions: clinical, economic and technical issues. *Radiol Med* 2016; **121**: 315–22. doi: <http://dx.doi.org/10.1007/s11547-015-0606-1>
78. Masciocchi C, Arrigoni F, La Marra A, Mariani S, Zugaro L, Barile A. Treatment of focal benign lesions of the bone: MRgFUS and RFA. *Br J Radiol* 2016; 20150356. doi: <http://dx.doi.org/10.1259/bjr.20150356>

79. Masciocchi C, Zugaro L, Arrigoni F, Gravina GL, Mariani S, La Marra A, et al. Radio-frequency ablation *versus* magnetic resonance guided focused ultrasound surgery for minimally invasive treatment of osteoid osteoma: a propensity score matching study. *Eur Radiol* 2015. Epub ahead of print. doi: <http://dx.doi.org/10.1007/s00330-015-4111-7>
80. Arrigoni F, Gregori LM, Zugaro L, Barile A, Masciocchi C. MRgFUS in the treatment of MSK lesions: a review based on the experience of the University of L'Aquila, Italy. *Transl Cancer Res* 2014; **3**: 442–8. doi: <http://dx.doi.org/10.3978/j.issn.2218-676X.2014.10.04>
81. Masciocchi C, Conchiglia A, Gregori LM, Arrigoni F, Zugaro L, Barile A. Critical role of HIFU in musculoskeletal interventions. *Radiol Med* 2014; **119**: 470–5. doi: <http://dx.doi.org/10.1007/s11547-014-0414-z>
82. Zoccali C, Rossi B, Zoccali G, Barbarino E, Gregori L, Barile A, et al. A new technique for biopsy of soft tissue neoplasms: a preliminary experience using MRI to evaluate bleeding. *Minerva Med* 2015; **106**: 117–20.
83. McCabe PS, Maricar N, Parkes MJ, Felson DT, O'Neill TW. The efficacy of intra-articular steroids in hip osteoarthritis: a systematic review. *Osteoarthritis Cartilage* 2016. Epub ahead of print. doi: <http://dx.doi.org/10.1016/j.joca.2016.04.018>
84. Wilson JJ, Lee KS, Chamberlain C, DeWall R, Baer GS, Greatens M, et al. Intra-tendinous injections of platelet-rich plasma: feasibility and effect on tendon morphology and mechanics. *J Exp Orthop* 2015; **2**: 5. doi: <http://dx.doi.org/10.1186/s40634-014-0018-5>
85. Wesner M, Defreitas T, Bredy H, Pothier L, Qin Z, McKillop AB, et al. A pilot study evaluating the effectiveness of platelet-rich plasma therapy for treating degenerative tendinopathies: a randomized control trial with synchronous observational cohort. *PLoS One* 2016; **11**: e0147842. doi: <http://dx.doi.org/10.1371/journal.pone.0147842>
86. Meheux CJ, McCulloch PC, Lintner DM, Varner KE, Harris JD. Efficacy of intra-articular platelet-rich plasma injections in knee osteoarthritis: a systematic review. *Arthroscopy* 2016; **32**: 495–505. doi: <http://dx.doi.org/10.1016/j.arthro.2015.08.005>