

A PROSPECTIVE EVALUATION

TREATMENT OF PAINFUL ADVANCED INTERNAL LUMBAR DISC DERANGEMENT WITH INTRADISCAL INJECTION OF HYPERTONIC DEXTROSE

Matthew R. Miller, DSc, PA-C, Robert S. Mathews, MD, PhD, and K. Dean Reeves, MD

Background: Degenerative discs are thought to produce nerve root pain either mechanically or chemically. Particularly in the case of advanced degenerative disc disease, this clinical entity has often proven to be symptomatically resistant to peridural steroids, Intra-discal Electrothermoplasty (IDET) and direct surgical intervention. Exposure of irritated nerves to hypertonic dextrose is thought to have chemoneuromodulatory potential. Sustained pain reduction has been demonstrated in a pilot study involving injection of a combination of dextrose, glucosamine, chondroitin and dimethylsulfoxide into degenerative discs of patients with chronic low back pain of discogenic origin.

Objective: To assess the effects of

disc space injections of hypertonic dextrose in patients experiencing chronic advanced degenerative discogenic leg pain, with or without low back pain.

Study Design: Prospective consecutive patient series.

Methods: Patients with moderate to severe degenerative disc disease without herniation and with concordant pain reproduction with CT discography were included. All had failure of a physical therapy trial and substantial but temporary relief with two fluoroscopically guided epidural steroid injections.

Patients underwent bi-weekly disc space injection of a solution consisting of 50% dextrose and 0.25% Bupivacaine in the disc(s) found positive on discography. The study was performed in an out-patient

surgery center in the United States.

Outcome measures included an 11-scale numeric pain score (0-10).

Results: Each patient was injected an average of 3.5 times. Overall, 43.4% of patients fell into the sustained improvement group with an average improvement in numeric pain scores of 71%, comparing pre-treatment and 18 month measurements.

Conclusion: The results suggest that intradiscal injection of hypertonic dextrose may have a place in the management of pain arising from advanced lumbar degenerative disc disease.

Key Words: Degenerative disc disease, internal disc disruption, dextrose, discogenic pain, discography

The intervertebral disc is a complex structure that has become the focus of much attention in clinical practice and it has been suggested that degeneration of the intervertebral disc is a major source of low back pain. The concept of internal disc disruption, with and without herniation, was described by Crock (1), who introduced the concept and described the patho-

logic features of this pain entity. Recent literature (2) has shed further light into this phenomenon and indicates the existence of a biochemical/biomechanical model of lumbar discogenic pain. This calls into question the popular belief that a disc lesion can only cause pain by direct nerve compression from disc herniation (3-6). Clinical studies have shown that fewer than 30% and as few as 1% of low back problems can be legitimately ascribed to nerve root compression (7-9).

Internal disc disruption is a process by which biochemical changes involving phospholipase A2, substance P and increased fibrinolytic activity ultimately lead to degeneration. The aging disc suffers progressive decline in nutrition as a result of an alteration in diffusion, diminished blood supply at the periphery of the annulus fibrosis and within the vertebral bodies, and decreasing matrix water. It has been sug-

gested that a reduction in proteoglycan synthesis leads to decreased production and maintenance of the disc matrix, triggering the cascade of degeneration (10).

Repetitive axial loading of the lumbar intervertebral disc results in fatigue failure, disruption of internal collagen fibrils and progressive infiltration of the nucleus pulposus into the annular fibers. Clinical and pathoanatomic investigations, including discography, have shown that pathways frequently exist between the degenerative nucleus pulposus and the adjacent nerve root. Pain can occur as a result of compression or traction of nociceptive fibers within the disc as well as by release of irritating chemical by-products through tears in the annulus fibrosis of the disc. The precise pathophysiologic mechanism by which chemical mediators within the intervertebral disc produce hyperalgesia is not clear. It has been speculated that

From: Lebanon Anesthesia Associates, Lebanon, Pennsylvania; Orthopedics of Lancaster, PSI, Lancaster, PA, and Department Of Physical Medicine and Rehabilitation, University of Kansas, Kansas City, KS.

Address Correspondence:

Matthew R. Miller, DSc, PA-C, 830 Tuck Street, Lebanon, PA 17042

Email: mfbtmiller@verizon.net

Conflict of Interest: None

Disclaimer: There was no external funding in preparation of this manuscript.

Manuscript received on 3/20/2006

Revision received on 3/30/2006

Accepted for publication on 4/02/2006

there is proliferation of sensory nerve fibers containing calcitonin gene-related peptide in the end-plate region and vertebral body adjacent to the degenerative disc. The increase in the density of sensory nerves and the presence of cartilage plate defects suggest a potential role of endplates and vertebral bodies as pain generators in patients with degenerative intervertebral discs (11).

Weinstein et al (12) investigated the pain reproduced by discography and concluded that sensitized annular nociceptors may create symptoms via neurochemical changes within the disc. Kawakami et al (13) hypothesized that these chemicals may be transported into the axons of a nerve root and initiate production of inflammatory agents such as prostaglandins, which may lead to radicular pain. Byröd et al (14) demonstrated a direct transport route to the axons of the spinal nerve roots and suggested that the chemical produced in the epidural space may be able to alter the excitability of C fibers.

Low back and sciatic pain can be present even in the apparent absence of distinct morphologic changes; conversely, many patients report no pain, even in the presence of marked degeneration. The treatment of pain arising from the severely degenerative lumbar intervertebral disc is difficult and controversial, with many patients failing conservative treatment and ultimately requiring lumbar arthrodesis. However, the significantly invasive nature of the surgery combined with poor predictability of pain relief often leads these patients to defer surgical intervention.

There is increasing interest in the development of physiologic treatment options that address the underlying causes of disc degeneration and pain (15-19). Injection therapy is one such alternative that places a symptom modifier and/or repair stimulant directly into degenerated and painful lumbar intervertebral discs.

Patients with radicular leg pain with or without low back pain, suspected as being associated with evident single or multi-level moderately severe to severe degenerative lumbar disc disease, demonstrate typically non-focal neurological examinations, yet are experi-

encing unrelenting pain. MRI examination in these cases may reveal desiccative disc changes but no significant alteration in the outer disc contour. In the general population, these patients fail to achieve an optimal response to prevailing non-operative therapies that include physical and manipulative therapies as well as epidural steroid injections, zygapophysial and sacroiliac joint injections. Further, due to severity of disc involvement, they tend to fall outside of the known indications for intradiscal electrothermoplasty (IDET) (9) and are often referred for surgical arthrodesis or disc replacement.

In addition to the wide variety of existing interventional pain techniques, the present authors had been using hypertonic dextrose solution to treat patients with spine pain complaints found to be arising from the fibro-osseous junctions (entheses) of various tendons and ligaments, including the interspinous, intertransverse, iliolumbar, sacroiliac, and multifidi muscles, as well as other tough soft tissue periosteal attachments. This treatment is based upon the principles of prolotherapy (Also called regenerative injection therapy (RIT)). The Latin word *proli* means offspring. A current definition of prolotherapy is *chemomodulation of collagen through repetitive stimulation of inflammatory and proliferative phases in a sophisticated process of tissue regeneration and repair, mediated by numerous growth factors leading to restoration of tensile strength, elasticity, increased mass and load bearing capacity of connective tissue* (20). In vitro exposure of human cells to extracellular dextrose concentrations as little as 0.6% (normal intracellular concentration approximates 0.1%) leads to elevation of as many as 15 different genes within minutes to hours of cellular exposure, including those of key growth factors (21, 22).

The authors found that by increasing the (end) concentration of the dextrose to 20-25% in the injectate, patients were reporting improvement in their pain complaints often after one injection into painful osteoarthritic knees, elbows, shoulders and carpometacarpal joints so as to suggest a chemoneuromodulatory benefit. This clin-

ical effect of dextrose has been validated in the literature (23-25). Further, as it was recognized that the physiologic makeup of the disc annulus was greatly similar to fibrous connective tissue, the authors hypothesized that intradiscal injection of hypertonic dextrose might result in improvement of discogenic pain in patients with moderately severe to severe degenerative lumbar intervertebral discs who had failed conservative treatment efforts to that point.

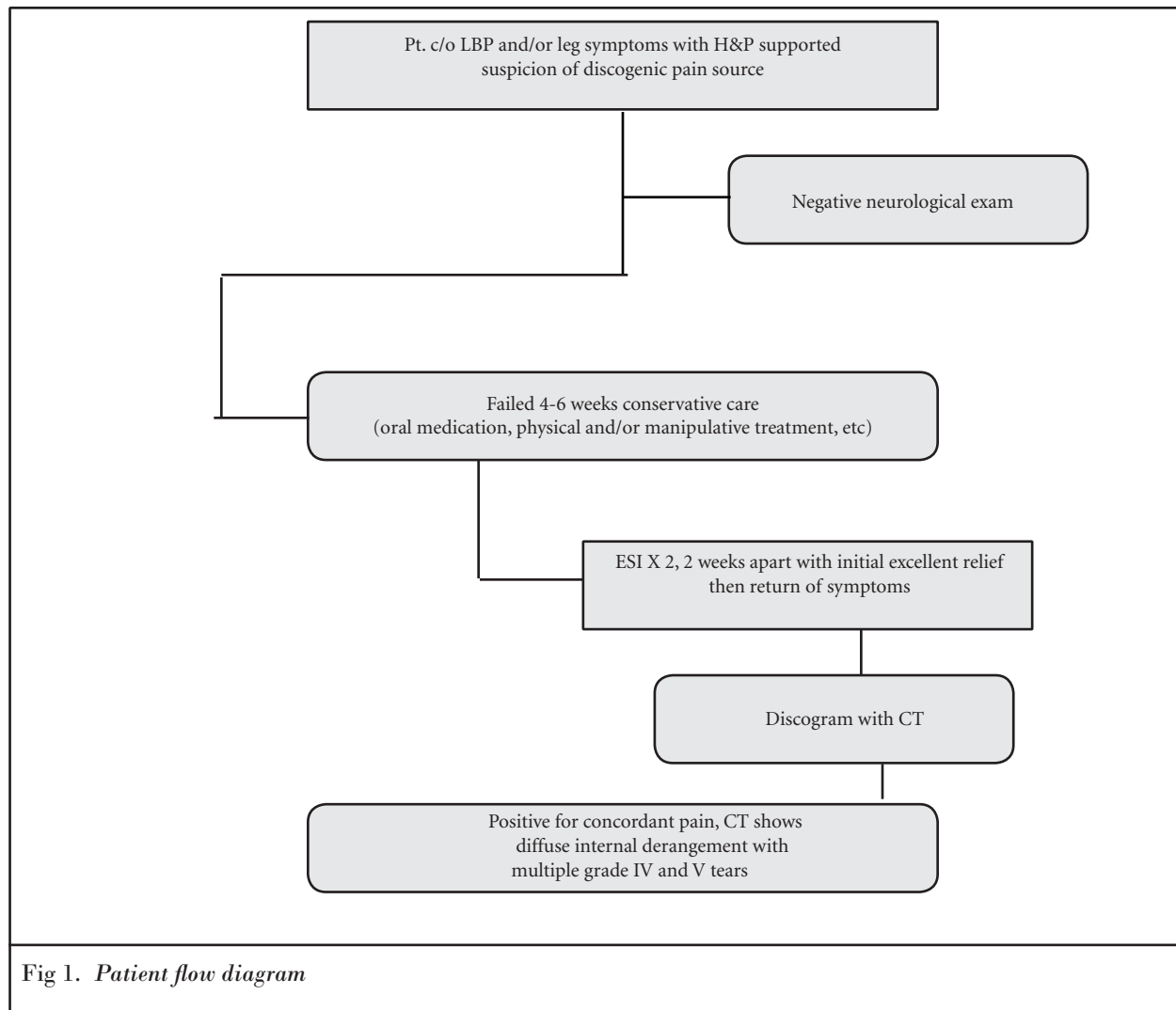
METHODS

The patient population was chosen from consecutive patients evaluated for leg pain with or without back pain and with normal neurological examination. Duration of pain was not a hard requirement, but proceeding through the evaluation and conservative treatment process generally took six months. Previous laminectomy/discectomy did not disqualify the patient as long as relief of symptoms for at least two years occurred, with subsequent event-induced exacerbation of symptoms.

All patients were given an explanation of the purpose of this study and an opportunity for discussion. They were also advised of the associated risks and given the choice as to whether or not they wanted to participate. Informed consent was then obtained. Appropriate precautions were taken to protect the privacy and anonymity of all of the patients participating in this study.

Initial work-up included history and physical examination combined with weight-bearing plain film radiographs and CT or MRI. All patients were entered into a conservative treatment program to include physical therapy and/or chiropractic care as well as oral medication for symptom reduction. Those patients that continued to experience pain were selected for further study based upon a diagnostic/treatment algorithm created by the authors for this study (Fig 1).

Thus, two fluoroscopically guided epidural steroid injections were performed two weeks apart. If this led to complete or near complete pain relief (80-100%) followed by return of symptoms, patients then underwent discography followed by CT scan to determine



a level-specific concordant pain generator and to assess the disc morphology. The ultimate intent was to demonstrate if pain from moderate to severe disc disease without significant disc bulge or frank HNP would respond to hypertonic dextrose. Patients were enrolled in the study only if CT discography revealed the following:

1. Concordant pain reproduction.
2. Negative pain production with testing of at least one other level.
3. CT evidence of multiple grade IV or V tears of the annulus fibrosis (Fig 2) at one or more levels, based on the modified Dallas criteria (26) indicating moderate, moderately severe, or severe desiccative disc disease.

4. No significant change in the outer contour of the disc (no significant bulge or frank HNP)

If extravasation of contrast had occurred during the discogram for that particular patient, we expected that subsequent therapeutic injection would similarly extravasate. However, extravasation only occurred in two patients with contrast volumes less than 3 mL during the discogram and in 14 patients with contrast volumes in excess of 3 mL.

Prior to the first treatment, patients filled out a 0-10 numeric pain scale (0 = no pain; 10 = maximal pain) to describe the severity of their leg pain. Then, they received an intradiscal injection of 50% dextrose in water, mixed

50:50 with bupivacaine 0.25% plain, to a total volume of 3 mL. Thus the final concentration of dextrose in the injectate became 25%. Injections were performed bi-weekly under fluoroscopic guidance and the needle insertion was on the side of greatest symptomatic complaint. A single puncture of the disc was created using a 5 or 7 inch Becton Dickinson 22 gauge Quincke tip spinal needle (single needle technique). One half of the injectate was placed as close to the center of the disc as the approach window would allow based upon the local anatomy. The remainder was injected into the estimated middle and outer thirds of the disc, as the needle was withdrawn. An average rate of injection was utilized, so as to allow the injectate

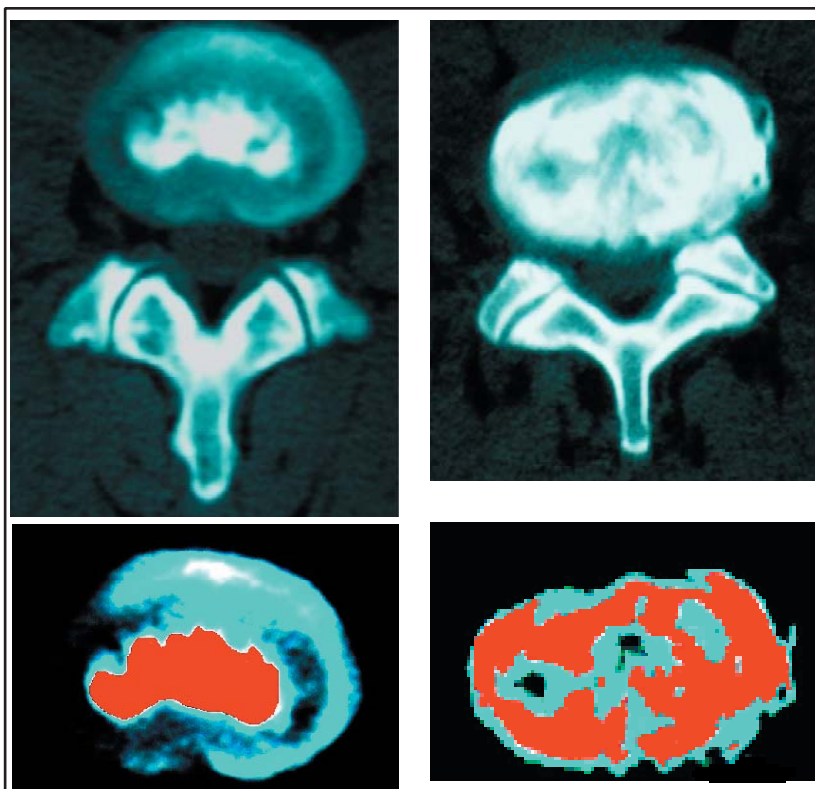


Fig 2. Post discogram axial CT images of a normal disc (top left) and abnormal disc (top right)- Below are the same discs with computer contrast and color enhancement added to reveal separation of nuclear (red/dark gray) and annular (blue-green/light gray) regions.

to reasonably diffuse into the discal environment (5-10 seconds).

Prior to each bi-weekly injection the patients did again complete the 0-10 numeric pain scale. Treatment was halted after three injections if the patients were non-responders (defined as less than 20% improvement in pain scale), or if they experienced a significant exacerbation of pain that persisted until the time of the next scheduled injection, such that they were unwilling to continue. Treatment was also halted if the pain rating reduced to 2 or less following the second injection, expecting that further stabilizing effect would occur over time. Patients were offered up to five treatments if they were experiencing a progressive reduction in pain, but had the option of stopping any time their response was considered by them to be satisfactory. To ensure a minimum of six months of follow-up, phone or clinic contact was made

with each patient at six months following the initial treatment of the last patient treated.

RESULTS

Between January 2001 and December 2002, 76 out of 737 patients with leg pain, with or without low back pain, were found to have concordant symptoms on discography and post discography CT with moderate to severe desiccative disc disease. Nine of these patients had previously undergone successful laminectomy/discectomy at one or more levels with good relief for at least two years followed by a subsequent event-induced exacerbation of symptoms. There were 41 males and 35 females. The age range of these patients was 21 to 90 years with a mean of 55 years. Duration of pain complaints ranged from 2-240 months with a mean of 39 months. Only two patients in this group had pain less

than six months (one at two months and the other three months).

The average number of treatments was 3.5 (range 1 to 6) and the average number of discs treated was 1.7 (range 1 to 3). Patients were followed for a minimum of six months (6 to 41 months with a mean of 18 months) and were grouped for data analysis according to response pattern (Fig 3). Thirty-seven patients were non-responders with either less than 20% improvement (31/37) or a temporary flare of pain (6/37). Six were temporary responders, with return to baseline pain by the time of last contact. The duration of follow up had large variability (six weeks to 41 months) since non-responders did not receive treatment or extended follow-up after the third bi-weekly injection or after an injection followed by flare. Therefore, 43.4% (33/76) of patients showed a sustained treatment response. Fig. 4 displays numeric pain score data for responders at 0 and two months and at final follow-up. The mean numeric 0-10 (0= no pain and 10=maximal pain) pain scale ratings and standard deviations were 8.9 (S.D. 1.4) at study entry, 2.5 (S.D. 2.0) at two months and 2.6 (S.D. 2.2) at 18 months in this group. The average improvement in the numeric pain score was 71%.

The average age of responders was very similar to the group as a whole at 56 (29 to 90). The duration of pain was similar, with a mean of two years nine months. The average number of treatments was 3.9 (range 1 to 5) and the average number of discs treated was 1.7 (range 1 to 3). The durability of response was reflected in the average number of treatments. Those that stopped early did not require further injection. Of the 33 responders, all but four reached a pain score rating of 4 or less at final follow up. Since 33 of 39 initial responders sustained a long-term response, patients who responded to three injections were 85% likely (33/39) to sustain a long-term response.

Of the 37 non-responders, six had treatment halted due to a significant pain exacerbation. Four of the six had pain resolve to baseline with pain medication and a prednisolone dose pack

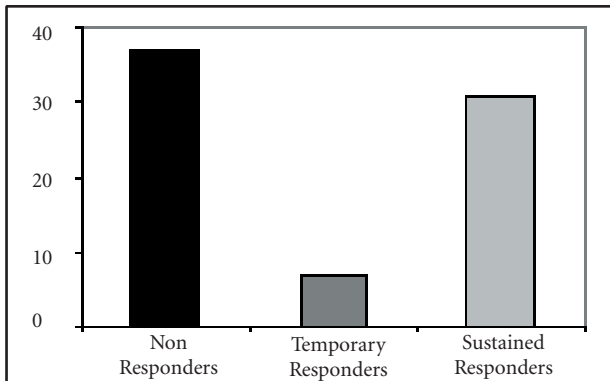


Fig 3. Intradiscal dextrose response patterns

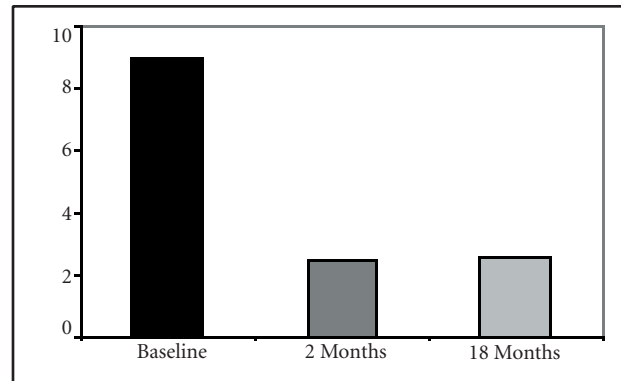


Fig 4. Pain scores in responders

within two weeks and two required intradiscal steroid injection with resolution of flare, to baseline, within six weeks.

We observed no evidence of disc space infection, neurological sequelae, or end plate fracture at any time in association with the diagnostic and treatment protocol.

DISCUSSION

A significant number of patients obtained marked benefit promptly after a single injection. Our treatment solution of 50% dextrose/0.25 bupivacaine has an end concentration osmolarity of approximately 1423 mOsm (1265 dextrose + 158.5 bupivacaine). Due to this high osmolarity, we hypothesize that the rapid onset of pain relief is attributable to chemoneuro-modulation of adjacent nociceptors. The hyperosmolar solution may also result in modulation of local vascular hemodynamics, leading to a reduction in nociceptive activity. The exact mechanism by which rapid improvement in pain occurred is not known. By contrast, the demonstrated durability of response is not likely to be solely from chemoneuromodulatory effects. The authors would suggest that sustained benefit results from the growth factor and tissue stabilizing effects of the dextrose upon the annulus fibrosus of the disc (17, 20).

Potential tissue stabilizing benefits of dextrose injection may occur in both cartilage and ligaments/tendons since chondrocytes and fibroblasts respond positively to similar growth fac-

tors. These growth factors (i.e., platelet derived growth factor, transforming growth factor beta, basic fibroblast growth factor, insulin like growth factor) are elevated by extracellular glucose concentrations of 0.6% or greater (21, 22). The hyperosmolar nature of the dextrose solution may be important as well. Exposure of a cell to an osmolarity change as little as 50 mOsm has also been found to activate enzymes (phosphate donors, also termed kinases) in human cells, which may have growth effects (27-29).

Dextrose (D-glucose) has also been found to have benefit in double blind studies on small and large osteoarthritic joints (24, 25). D-glucose, in addition to increasing multiple growth factors, has been found to suppress potential disrepair factors, including such interleukins 2, 6 and 10 (30). Elevated D-glucose concentrations in a joint also appear to reduce cartilage-damaging-protein (collagenase) levels (31). Proving effects on ligaments is more difficult. Ultrasound studies are in pre-publication at this time to demonstrate structural effects. Direct machine measurement is difficult but a sentinel study on anterior cruciate ligament (ACL) ligament laxity with objective arthrometric measurement (KT-1000) demonstrated the ability of simple 10% dextrose injection to tighten loose ACL ligaments (23). Clearly much work needs to be done on demonstrating similar effects on intervertebral disc structure.

All patients that experienced pain

relief demonstrated moderately severe to severe degenerative disc disease and it is possible that the relief occurred because the discs were predominantly chemically sensitive. Those patients experiencing initial relief of pain from the local anesthetic, with subsequent return of that pain, may well have mechanically sensitive discs and the current treatment regimen was insufficient due to treatment design flaws (inadequate chemical concentration, insufficient number of treatments, failure to consistently direct medication to the nociceptive fibers and other factors).

Klein et al (17) studied the potential benefit from the injection of a solution comprised of glucosamine and chondroitin sulfate combined with hypertonic dextrose and dimethylsulfoxide (DMSO). This solution was injected into degenerative lumbar discs of 30 patients suffering from chronic intractable low back pain. These patients had previously failed conservative therapy and all demonstrated a positive discogram at one or more levels as evidenced by concordant pain provocation combined with morphologic disc abnormalities. Seven of these patients had failed to respond to IDET. A similar solution, though without the chondroitin sulfate, was injected into the same level zygapophysial joints at the time of the disc injection. Seventeen patients reported an average reduction in the numeric pain score of 76%, which is an encouraging result, given the nature of the involved pathology. However, the authors acknowledged that the decision to empirically treat the same level

zygapophysial joints complicated their ability to discern the relative contribution of the intervertebral disc and zygapophysial joints to the total pain perception for a given patient. Additionally, their use of a solution with several components limits the ability to measure whether or not and to what extent each component contributes to the benefit.

The present authors chose to test the relative benefit of a single active component in the treatment of a single known nociceptive source based upon the patient presentation and CT discography results. The percentage of responders suggests that the disc alone may act as a primary nociceptive source in the three joint complex and benefit may not always require same level zygapophysial injection. One unanswered question for further study, therefore, is a means by which we can determine which patients require treatment of the disc alone and which would require treatment of the entire three-joint complex.

Although this study was more than double the size of an earlier pilot study on 25% dextrose disc injection (32) this present work should also be considered only a pilot study as it was neither randomized, controlled, nor blinded. The results will have to be validated through a study of more stringent design. Such a construct is being developed and consideration has been given to utilizing blinded randomization and patient evaluation, a placebo group, a larger patient base and treatment group and manometrically assisted discography.

The two patients that had pain less than six months at the time of treatment were still reporting 0-2/10 pain ratings at 33 and 41 months, respectively. Patient # 1 was a 48-year-old male who had received three serial injections of the previous laminectomy/discectomy level (L4-5). Patient #2 was a 50-year-old male, had no history of surgery and received four serial injections at L4-5 and L5-S1, based upon the results of the discogram.

The authors considered that patients experiencing significant improvement after only one injection may have benefited from the simple dilution of

chemical irritants from within the disc. However, pain relief derived from such a mechanism would only be expected to last only as long as it took for the chemical irritants to again coalesce, leading to return of pain impulses over the relative short term. There appeared to be no relationship between those patients who experienced temporary increases in pain associated with the dextrose, and whether they were responders or non-responders.

From a technical point of view, discs with a notable loss of disk height are not appropriate candidates for IDET; in many, the increased degree of nuclear disorganization further serves to make intradiscal navigation difficult (33). Further, a degree of internal derangement generally beyond a discrete posterior grade 3, as well as anterior or lateral tearing, will not tend to be associated with an optimal result from IDET (15). Despite the localized nature of annular pathology of the IDET treated discs, the average reductions in pain were 2.4 in one study (9) and 1.8 in another (16). The patients treated in the present consecutive patient collection had discs with grade 4 and 5 annular tears, moderate, moderately severe and severe loss of axial disc height and diffuse contrast opacification of the disc on post-discogram CT.

In looking at the relationship between the degree of disc degeneration evident on the post-discogram CT and the degree of improvement from the dextrose injections, we found no clear correlation. This is to say that there were patients with diffuse internal annular derangement who experienced benefit from the injections and those who were no better. The key may lie in the degree of nerve fiber in-growth as it relates to the degree of disc degeneration, the exact number and location of these fibers, and whether the fibers are chemical or mechanical in type. Further, discographic pain interpretation of discs of the type described in the study patient type is challenging due to the degree of internal disc discontinuity and the prospect of false positive and false negative results has been considered.

Discography induces pressures that differ from the pressure distribution of normal activities, producing stimulation by means of an expanding force, with peak force on the nucleus pulposus. Normal activities involve compression forces with peak pressures occurring in the outer annulus. During normal activities over a range of loading conditions, the largest stresses in normal discs appear to occur in the annulus, not the nucleus (34). Thus, the relationship between distributed loads upon the severely degenerated annulus, resulting vertebral endplate deformation and resulting pain generation may stretch the diagnostic limits of discography in terms of patient selection. However, no clearly good alternative exists at this time and so it remains our best test.

CONCLUSION

The current work suggests that intradiscal injection of hypertonic dextrose may have a place in the management of pain arising from advanced lumbar degenerative disc disease. To have clear responders and non-responders suggests a manageable subset of patients that can be identified by about 6-8 weeks post-treatment onset (3 injections at bi-weekly intervals and 2 week follow-up). It is most encouraging that the reductions in numeric pain scale scores were so firmly maintained in patients with uniformly moderate to severe disc desiccation at an average of 18 months. Those patients who experienced no appreciable improvement from the treatment were not worse in any sustained way. Further defined study is clearly indicated toward a better understanding of the pathophysiology of painful degenerative discs, through which the evolution of pain management procedures and related treatments will occur.

The results represent our observations, by way of direct experience in this field and in consideration of existing scientific literature. The described treatment protocol is not intended to represent guidelines for treatment or a standard of care.

AUTHOR AFFILIATION:

Matthew R. Miller, D.Sc., PA-C
Lebanon Outpatient Surgery Center
830 Tuck Street
Lebanon, PA 17042
Email: mfbtmiller@verizon.net

Robert S. Mathews, MD, PhD
Penn Orthopedics of Lancaster/ PSI
554 N. Duke Street
Lancaster, PA 17602-2226

K. Dean Reeves, MD
Clinical Associate Professor
Physical Medicine and Rehabilitation,
University of Kansas
4740 El Monte
Shawnee Mission, KS 66205
Email: dreeves1@kc.rr.com

REFERENCES

- Crock HV. Internal disc disruption: A challenge to disc prolapse fifty years on. *Spine* 1986; 11:650-653.
- Guiot BH, Fessler RG. Molecular biology of degenerative disc disease. *Neurosurgery* 2000; 47:1034-1040.
- Coppes MH, Marani E, Thomeer RTWM, Groen GJ. Innervation of "painful" lumbar discs. *Spine* 1997; 22:2342-2350.
- Freemont AJ, Watkins A, Maitre CL, Baird P, Jeziorska M, Knight MTN, Ross ERS, O'Brien JP, Hoyland JA. Nerve growth factor expression and innervation of the painful intervertebral disc. *J Pathol* 2002; 197:286-292.
- Kitano T, Zerwekh J, Usui Y, Edwards ML, Flicker PL, Mooney V. Biochemical changes associated with the symptomatic human intervertebral disk. *Clin Orthop Rel Res* 1993; 293:372-377.
- Sehgal N, Fortin JD. Internal disc disruption and low back pain. *Pain Physician* 2000; 3:143-157.
- Friberg S. Lumbar disc herniation in the problem of lumbago sciatica. *Bull Hosp Joint Dis* 1954; 15:1-20.
- Horal J. The clinical appearance of low back disorders in the city of Gothenburg, Sweden. *Acta Orthop Scand Suppl* 1969; 118:1-108.
- Pauza KJ, Howell S, Dreyfuss P, Pelouza JH, Dawson K, Bogduk N. A randomized, placebo-controlled trial of intradiscal electrothermal therapy for the treatment of discogenic low back pain. *Spine J* 2004; 4:27-35.
- Lee CK, Kopacz KJ. Lumbar discogenic pain and instability. Orthopaedic knowledge update. *Spine* 2002; 35:333-342.
- Brown MF, Hukkanen, McCarthy ID, Redfern DR, Battern JJ, Crock HV, Hughes SP, Polak JM. Sensory and sympathetic innervation of the vertebral endplate in patients with degenerative disc disease. *J Bone Joint Surg Br* 1997; 79:147-153.
- Weinstein J, Claverie W, Givson S. The pain of discography. *Spine* 1988; 13:1344-1348.
- Kawakami M, Tamaki T, Hayashi N, Hashizume H, Nishi H: Possible mechanism of painful radiculopathy in lumbar disc herniation. *Clin Orthop* 1998; 351:241-251.
- Byröd G, Olmarker K, Konno S, Larsson K, Takahashi K, Rydevik B. A rapid transport route between the epidural space and the intraneural capillaries of the nerve roots. *Spine* 1995; 20:138-143.
- Derby R, Eek B, Chen Y, O'Neill C, Ryan D. Intradiscal electrothermal annuloplasty (IDET): A novel approach for treating chronic discogenic back pain. *Neuromodulation* 2000; 2:82-88.
- Derby R, Eek B, Lee SH, Seo KS, Kim BJ. Comparison of intradiscal restorative injections and intradiscal electrothermal treatment (IDET) in the treatment of low back pain. *Pain Physician* 2004; 7:63-66.
- Klein RG, Eek BCJ, O'Neill CW, Elin C, Mooney V, Derby RR. Biochemical injection treatment for discogenic low back pain: a pilot study. *Spine J* 2003; 3:220-226.
- Saal JS, Saal JA. Management of chronic discogenic low back pain with a thermal intradiscal catheter. *Spine* 2000; 3:382-388.
- Walsh AJL, Bradford DS, Lotz JC. In vivo growth factor treatment of degenerated intervertebral discs. *Spine* 2004; 2:156-163.
- Linetsky FS, Manchikanti L. Regenerative injection therapy for axial pain. *Tech Reg Anesth Pain Manage* 2005; 9:40-49.
- Murphy M, Godson C, Cannon S, Kato S, Mackenzie HS, Martin F, Brady HR. Suppression subtractive hybridization identifies high glucose levels as a stimulus for expression of connective tissue growth factor and other genes in human mesangial cells. *J Biol Chem* 1999; 274:5830-5834.
- Oh JH, Ha H, Yu MR, Lee HB. Sequential effects of high glucose on mesangial cell transforming growth factor-beta 1 and fibronectin synthesis. *Kidney Int* 1998; 54:1872-1878.
- Reeves KD, Hassanein K. Long term effects of dextrose prolotherapy for anterior cruciate ligament laxity: A prospective and consecutive patient study. *Altern Ther Health Med* 2003; 9:58-62.
- Reeves KD, Hassanein K. Randomized prospective double-blind placebo-controlled study of dextrose prolotherapy for knee osteoarthritis with or without ACL laxity. *Alt Ther Hlth Med* 2000; 6:68-80.
- Reeves KD, Hassanein K. Randomized prospective placebo-controlled double-blind study of dextrose prolotherapy for osteoarthritic thumbs and fingers (DIP, PIP and trapeziometacarpal joints): Evidence of clinical efficacy. *J Alt Compl Med* 2000; 6:311-320.
- Sachs BL, Vanharanta H, Spivey MA, Guyer RD, Videman T, Rashbaum RF, Johnson RG, Hochschuler SH, Mooney V. Dallas discogram description. A new classification of CT/discography in low back disorders. *Spine* 1987; 12:287-294.
- Berl T, Siriwardana G, Ao L, Butterfield LM, Heasley LE. Multiple mitogen-activated protein kinases are regulated by hyperosmolality in mouse IMCD cells. *Am J Physiol* 1997; 272:305-811.
- Okuda Y, Adroque HJ, Nakajima T, Mizutani M, Asano M, Tachi Y, Suzuki S, Yamashita K. Increased production of PDGF by angiotensin and high glucose in human vascular endothelium. *Life Sci* 1996; 59:1455-1461.
- Caruccio L, Bae S, Liu AY, Chen KY. The heat shock transcription factor HSF1 is rapidly activated by either hyper- or hypoosmotic stress in mammalian cells. *Biochem J* 1997; 327:341-347.
- Reinhold D, Ansoorge S, Schleicher ED. Elevated glucose levels stimulate transforming growth factor-beta (TGF-beta1), suppress interleukin IL-2, IL-6 and IL-10 production and DNA synthesis in peripheral blood mononuclear cells. *Horm Metab Res* 1996; 28:267-270.
- Singh R, Song RH, Alavi N, Pegoraro AA, Singh AK, Leehey DJ. High glucose decreases matrix metalloproteinase-2 activity in rat mesangial cells via transforming growth factor-beta1. *Exp Nephrol* 2001; 9:249-257.
- Mathews RS, Miller M, Bree S. Treatment of mechanical and chemical discopathy by dextrose 25%. *J Min Invas Tech* 2001; 1:58-61.
- Wetzel FT, McNally TA. Treatment of chronic discogenic low back pain with intradiscal electrothermal therapy. *J Am Acad Orthop Surg* 2003; 11:6-11.
- Adams MA, McNally DS, Nolan P. Stress distributions inside intervertebral discs. The effects of age and degeneration. *J Bone Joint Surg Br* 1996; 78:965-972.